

---

# REVISED EUROPEAN TRAINING CURRICULUM FOR RADIOLOGY

**Edition March 2016**

Curriculum for the Level I Training Programme (Years 1-3)

---

Curriculum for the Level II Training Programme (Years 4-5)

---

OFFICIALLY SUPPORTED BY THE FOLLOWING ESR INSTITUTIONAL MEMBER SOCIETIES (as of October, 2014):

NATIONAL SOCIETIES	
AUSTRIA	Austrian Roentgen Society
BELARUS	Belarussian Society of Radiologists
BELGIUM	Belgian Radiological Society
BOSNIA AND HERZEGOVINA	Association of Radiology of Bosnia & Herzegovina
BULGARIA	Bulgarian Association of Radiology
CROATIA	Croatian Society of Radiology
CYPRUS	Cyprus Radiological Society
CZECH REPUBLIC	Czech Radiological Society
DENMARK	Danish Society of Radiology
ESTONIA	Estonian Society of Radiology
FINLAND	Radiological Society of Finland
FRANCE	French Society of Radiology
GEORGIA	Georgian Association of Radiologists
GERMANY	German Radiological Society
GREECE	Hellenic Radiological Society
HUNGARY	Hungarian Society of Radiologists
ICELAND	Radiological Society of Iceland
IRELAND	Faculty of Radiologists, Royal College of Surgeons in Ireland
ISRAEL	Israel Radiological Association
ITALY	Società Italiana di Radiologia Medica
KAZAKHSTAN	Radiological Society of Kazakhstan
LATVIA	Latvian Association of Radiologists
LITHUANIA	Lithuanian Radiologists' Association
MALTA	Maltese Association of Radiologists
NETHERLANDS	Radiological Society of the Netherlands
NORWAY	Norwegian Society of Radiology
POLAND	Polish Medical Society of Radiology
PORTUGAL	Portuguese Society of Radiology and Nuclear Medicine
ROMANIA	Romanian Society of Radiology and Medical Imaging
RUSSIA	Russian Association of Radiologists
SERBIA	Radiological Society of Serbia
SLOVAKIA	Slovak Radiological Society
SLOVENIA	Slovenian Association of Radiology
SPAIN	Sociedad Española de Radiología Médica
SWEDEN	Swedish Society of Medical Radiology
SWITZERLAND	Swiss Society of Radiology
TURKEY	Turkish Society of Radiology
UKRAINE	Association of Radiologists of the Ukraine

SUBSPECIALTIES AND ALLIED SCIENCES SOCIETIES	
CIRSE	Cardiovascular and Interventional Radiological Society of Europe
ESCR	European Society of Cardiac Radiology
ESER	European Society of Emergency Radiology
ESGAR	European Society of Gastrointestinal and Abdominal Radiology
ESHNR	European Society of Head and Neck Radiology
ESMOFIR	European Society of Molecular and Functional Imaging in Radiology
ESMRMB	European Society for Magnetic Resonance in Medicine and Biology
ESNR	European Society of Neuroradiology
ESOI	European Society of Oncologic Imaging
ESPR	European Society of Paediatric Radiology
ESSR	European Society of Musculoskeletal Radiology
ESTI	European Society of Thoracic Imaging
ESUR	European Society of Urogenital Radiology
EUSOBI	European Society of Breast Imaging
EuSoMII	European Society of Medical Imaging Informatics

OFFICIALLY SUPPORTED BY THE FOLLOWING ESR ASSOCIATE INSTITUTIONAL MEMBER SOCIETIES (as of November, 2014):

### NATIONAL SOCIETIES

ARGENTINA	Argentinian Society of Radiology
BOLIVIA	Bolivian Society of Radiology
BRAZIL	Brazilian College of Radiology
CHILE	Chilean Society of Radiology
CHINA	Chinese Society of Radiology
COLOMBIA	Colombian Association of Radiology
COSTA RICA	Costa Rican Association of Radiology
EGYPT	Egyptian Society of Radiology and Nuclear Medicine
HONDURAS	Honduran Society of Radiology
INDIA	Indian Radiological & Imaging Association
IRAN	Iranian Society of Radiology
IRAQ	Iraqi Association of Radiology
JAPAN	Japan Radiological Society
KOREA	Korean Society of Radiology
LEBANON	Lebanese Society of Radiology
MALAYSIA	Malaysian College of Radiology
MEXICO	Mexican Society of Radiology
MONGOLIA	Mongolian Radiological Society
PAKISTAN	Radiological Society of Pakistan
SAUDI ARABIA	Radiological Society of Saudi Arabia
SINGAPORE	Singapore Radiological Society
SOUTH AFRICA	Radiological Society of South Africa
SRI LANKA	Sri Lanka College of Radiologists
TUNISIA	Tunisian Society of Radiology
URUGUAY	Uruguayan Society of Radiology
UZBEKISTAN	Uzbekistan Radiology Society
VIETNAM	Vietnamese Society of Radiology and Nuclear Medicine
YEMEN	Yemen Society of Radiology

APPROVED BY:

UEMS  
(EUROPEAN UNION OF MEDICAL SPECIALISTS)



June 2013 Adaptation to the UEMS format

October 12, 2013 Endorsed by the UEMS Radiology Section

October 19, 2013 Endorsed by the UEMS Council

#### Copyright notice

You may take temporary copies necessary to browse this website on screen. Universities and National Societies dedicated to the promotion of scientific and educational activities in the field of medical imaging are entitled to use the material as a guideline for educational purposes, but appropriate credit must be given to the ESR. Material must be reproduced as originally published and full credit must be given to the original publication.

This copyright notice must not be altered or removed. This material is for non-commercial use only, any commercial use of the material in whole or in part is strictly prohibited.

This work is licensed under a [Creative Commons Attribution-NonCommercial-ShareAlike 4.0 International License](https://creativecommons.org/licenses/by-nc-sa/4.0/).

**REVISED**  
**EUROPEAN**  
**TRAINING**  
**CURRICULUM**  
**FOR RADIOLOGY**

I.	TRAINING REQUIREMENTS FOR TRAINEES	Page 7
	<b>Content of training and learning outcome</b>	Page 7
B-I:	LEVEL I TRAINING PROGRAMME (YEARS 1-3)	Page 9
	B-I-1 Breast Radiology	Page 11
	B-I-2 Cardiac and Vascular Radiology	Page 13
	B-I-3 Chest Radiology	Page 15
	B-I-4 Emergency Radiology	Page 18
	B-I-5 Gastrointestinal and Abdominal Radiology	Page 21
	B-I-6 Gynaecological and Obstetric Radiology	Page 24
	B-I-7 Head and Neck Radiology	Page 26
	B-I-8 Interventional Radiology	Page 28
	B-I-9 Musculoskeletal Radiology	Page 30
	B-I-10 Neuroradiology	Page 32
	B-I-11 Paediatric Radiology	Page 34
	B-I-12 Urogenital Radiology	Page 37
	B-I-13 Nuclear Medicine as basic training	Page 39
	B-I-14 Radiation Protection Education and Training	Page 41
	B-I-15 Principles of Imaging Technology & Molecular Imaging	Page 44
	B-I-16 Communication and Management	Page 49
	B-I-17 Research and Evidence-Based Medicine	Page 51
B-II:	LEVEL II TRAINING PROGRAMME (YEARS 4-5)	Page 52
	B-II-1 Breast Radiology	Page 54
	B-II-2 Cardiac and Vascular Radiology	Page 57
	B-II-3 Chest Radiology	Page 61
	B-II-4 Emergency Radiology	Page 69
	B-II-5 Gastrointestinal and Abdominal Radiology	Page 76
	B-II-6 Gynaecological and Obstetric Radiology	Page 86
	B-II-7 Head and Neck Radiology	Page 90
	B-II-8 Interventional Radiology	Page 96
	B-II-9 Musculoskeletal Radiology	Page 103
	B-II-10 Neuroradiology	Page 109
	B-II-11 Oncologic Imaging	Page 116
	B-II-12 Paediatric Radiology	Page 120
	B-II-13 Urogenital Radiology	Page 127
	<b>Organisation of Training</b>	Page 132
	A. Schedule and Length of Training	Page 132
	B. Curriculum of Training / Infrastructural Aspects	Page 135
	C. Assessment and Evaluation	Page 139
	D. Governance	Page 140
II.	TRAINING REQUIREMENTS FOR TRAINERS	Page 141
	<b>Process for recognition as trainer</b>	Page 141
	<b>Quality management for trainers</b>	Page 141
III.	TRAINING REQUIREMENTS FOR TRAINING INSTITUTIONS	Page 142
	<b>Process for recognition as training center</b>	Page 142
	A. Requirements on staff and clinical activities	Page 142
	B. Requirements on equipment and accommodation	Page 143
	<b>Quality management within training institutions</b>	Page 144

# PREFACE TO THE NEW EDITION OF THE EUROPEAN TRAINING CURRICULUM LEVEL I AND II

As every year, we present the new edition of the European Training Curriculum to the radiological community with revised and new content.

In this new edition the relevant organ-based chapters have been thoroughly reviewed, as always, according to the recommendations of the respective subspecialty societies. The revisions of the chapters for levels I and II on Cardiac and Vascular Radiology proposed by the European Society of Cardiac Radiology (ESCR) have been accordingly implemented. Furthermore, the updates proposed by the European Society of Gastrointestinal and Abdominal Radiology (ESGAR), the European Society of Neuroradiology (ESNR), and the European Society of Oncologic Imaging (ESOI) have been included in their relevant chapters for level II. In addition, the chapter on Gynaecological and Obstetric Radiology for level I and the chapters on Urogenital Radiology for both level I and II have been revised by the European Society of Urogenital Radiology (ESUR). Finally, the revisions suggested by the European Society of Thoracic Imaging (ESTI) as well as by the European Society of Breast Imaging (EUSOBI) have been implemented in their relevant chapters for both level I and II. To conclude, the European Society for Hybrid Medical Imaging (ESHI), established in May 2015, has revisited and updated the contents of the chapter "Nuclear Medicine as Basic Training" from level I.

In the present edition of March 2016, a new chapter on Emergency Imaging has been included, with content provided by the European Society of Emergency Radiology (ESER).

A chapter on Medical Imaging Informatics is currently being prepared by the European Society of Medical Imaging Informatics (EuSoMII).

I would like to thank the Board of Directors and the Executive Council as well as all individuals and Subspecialties and Allied Sciences Societies of the European Society of Radiology for their work and contribution to this document in constant adaptation to the continuous evolution of our specialty.

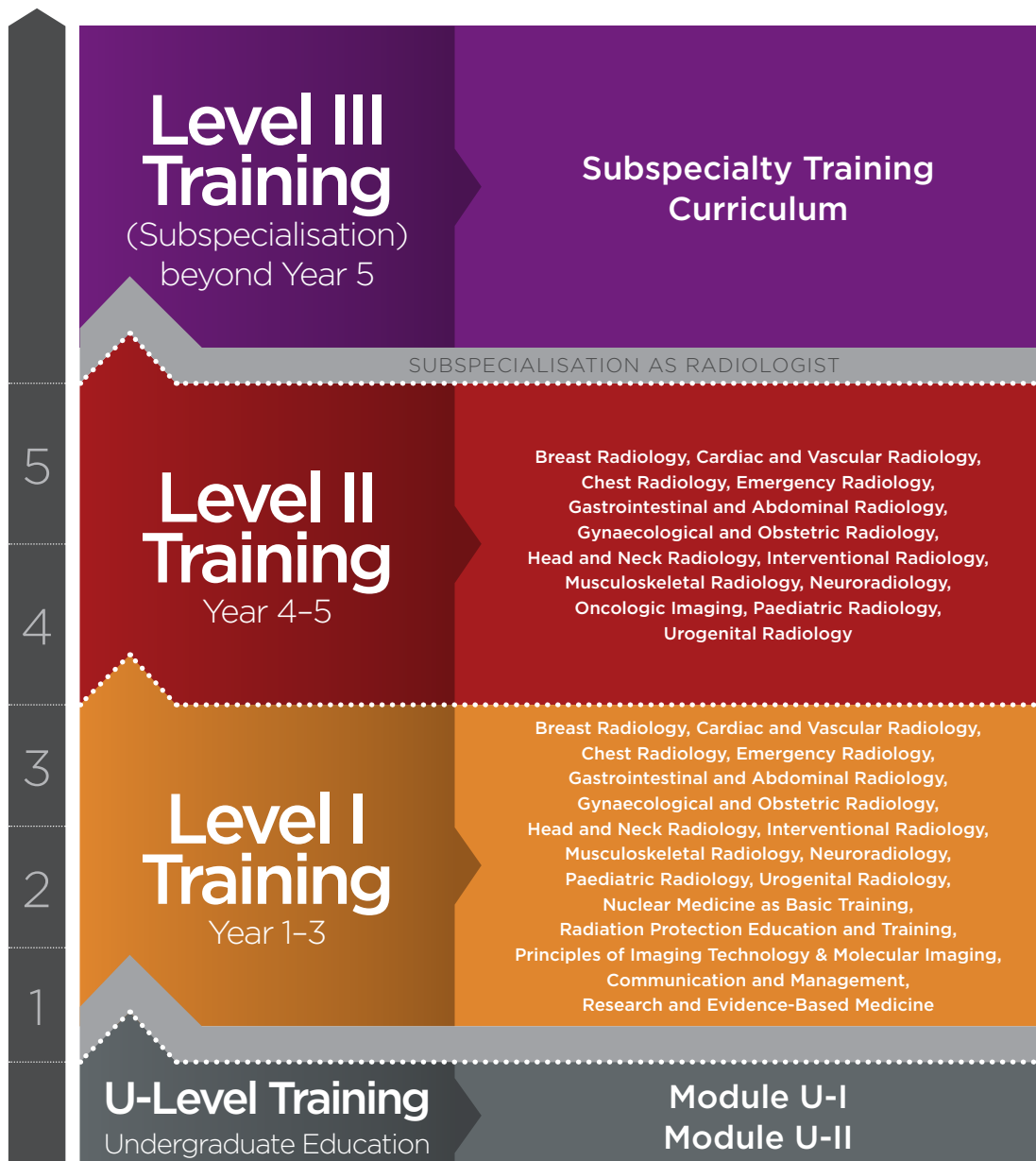Barcelona, February 9, 2016

Laura Oleaga  
Chairperson of the Education Committee of the ESR

# I. TRAINING REQUIREMENTS FOR TRAINEES

## 1. CONTENT OF TRAINING AND LEARNING OUTCOME

This chapter defines the contents of training and expected learning outcomes of trainees in radiology. Training shall be performed in several levels. The revised European Training Curriculum for Radiology continues to outline a five-year (3 + 2) training period, consisting of Level I Training over the first three years followed by a more flexible Level II Training with potential special interest (elective) rotations during the last two years. Full subspecialty training with consecutive subspecialisation can be performed after this five year training period, which corresponds to Level III training (not part of this curriculum).



In international higher and post-graduate education there has been an increasing focus on competencies, rather than just education inputs. Instead of just focussing on the “learning inputs”, the “learning outputs” have increasingly been in the centre of educational attention and endeavours. This led to concepts of Knowledge, Skills and Competences (KSCs) or of Knowledge, Skills and Attitudes (KSAs). These learning outcomes are less dependent on the times and routes of acquisition.

While the concept of “knowledge” has been the traditional basis for educational curricula providing lists of topics the trainee is expected to learn, the concepts of skills, competences and attitudes are more difficult to appreciate. The word “skill” is usually applied to describe a level of performing a particular task – this can be a motor task (e.g. performing an arterial puncture) or a cognitive task. The term “competences” has been subject of frequent debates in the past years with several different models being in use.

Competences tend to develop from an initially rule-based, inflexible behaviour to an intuitive understanding of the situation and comprehension of the crucial aspects of a situation. This development should be encouraged throughout the training.

The following training curriculum / syllabus is divided into two levels of training (Level I and Level II) and further subdivided into the different areas of training. These chapters are further divided into the following sections:

---

Knowledge: this section includes the main domains of theoretical knowledge the trainee should master in this specialty area

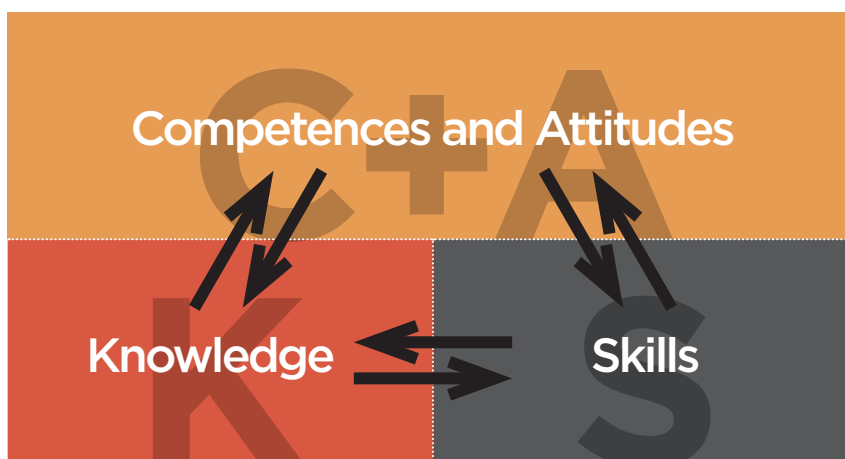
---

Skills: this section includes the key practical and clinical skills the trainee should acquire in this specialty area

---

Competences and attitudes: this section includes the competences to be mastered as well as the domains of professionalism the trainee should acquire in this specialty area

---





B-I:  
**LEVEL I  
TRAINING  
(YEARS 1-3)**

# LEVEL I TRAINING (YEARS 1-3)

**The subject content of the curriculum for Level I Training includes the following elements:**

B-I-1 Breast Radiology

B-I-2 Cardiac and Vascular Radiology

B-I-3 Chest Radiology

B-I-4 Emergency Radiology

B-I-5 Gastrointestinal and Abdominal Radiology

B-I-6 Gynaecological and Obstetric Radiology

B-I-7 Head and Neck Radiology

B-I-8 Interventional Radiology

B-I-9 Musculoskeletal Radiology

B-I-10 Neuroradiology

B-I-11 Paediatric Radiology

B-I-12 Urogenital Radiology

B-I-13 Nuclear medicine as basic training

B-I-14 Radiation Protection Education and Training

B-I-15 Principles of Imaging Technology & Molecular Imaging

B-I-16 Communication and Management

B-I-17 Research and Evidence-Based Medicine

## B-I-1 BREAST RADIOLOGY

### INTRODUCTION

The aim of this curriculum in breast imaging is to ensure that the trainee develops core knowledge of imaging normal breast and breast diseases that will form the basis for further training (if desired). It will also provide transferable skills that will equip the trainee for working as a specialist in any branch of radiology.

Physics and radiation protection are covered in separate courses and are not covered in detail unless specific to breast imaging.

### KNOWLEDGE

- To understand the anatomy of the female breast, axilla and associated structures and how they change with age
- To describe normal variants and abnormalities of the female breast
- To understand clinical practice relevant to breast imaging
- To describe radiographic techniques employed in diagnostic mammography
- To describe the principles of digital imaging and image processing pertinent to mammography, including standard cranio-caudal and medio-lateral oblique views, additional views, and tomosynthesis
- To understand physics of image production in mammography, particularly how they affect image quality
- To analyse and explain principles of current practice in breast imaging and breast cancer screening
- To know the risk/benefit analysis associated with breast cancer screening
- To describe the proper application of other imaging techniques in this specific field, such as ultrasound, MRI, or radionuclide imaging and to put these into a correct diagnostic pathway
- To describe the indications and contraindications for image-guided interventional breast procedures (fine needle aspiration, core needle biopsy, vacuum-assisted biopsy, presurgical localization)
- To recognize the different presentation of normal breast patterns at mammography, ultrasound, and MRI
- To distinguish the appearance of common benign diseases and of breast cancer on mammography, ultrasound, and MRI
- To understand principles and basic application of a standardized diagnostic categorization systems such as the ACR Breast Imaging Reporting and Data System (BI-RADS®) with reference to mammography, ultrasound, and MRI
- To describe the principles of communication specifically related to the breaking of bad news and consent

## SKILLS

- To perform ultrasound examinations of the breast under supervision
- To perform interventional breast procedures under ultrasound and X-ray guidance under supervision

## COMPETENCES AND ATTITUDES

- To justify diagnostic imaging examinations of the breast
- To choose the best-suited method for evaluating disorders of the breast
- To communicate with the patient in order to obtain informed consent prior to interventional procedures of the breast
- To choose optimal imaging parameters for mammography
- To apply techniques to reduce exposure doses of mammography
- To supervise and teach technical staff to ensure that appropriate images are obtained
- To report mammography, breast ultrasound, and breast MRI with respect to common breast diseases, using descriptors and diagnostic categories according standardized systems such as BI-RADS®
- To appreciate own limitations and to identify when it is appropriate to obtain assistance in interpreting and reporting breast images
- To communicate with patients and their relatives in order to explain the nature of benign breast disease
- To observe bad news being given to patients and their relatives
- To communicate with patients and their relatives to give bad news
- To participate in and to perform under supervision at multi-disciplinary breast conferences and tumour boards

## B-I-2 CARDIAC AND VASCULAR RADIOLOGY

### KNOWLEDGE

- To describe the normal anatomy of the heart and vessels including the lymphatic system as demonstrated by radiographs, contrast-enhanced CT and MRI
- To describe normal variants of the cardiac, vascular and lymphatic systems
- To understand the mean exposure doses of radiographs and of CT examinations cardiac and vascular systems
- To describe the principles of digital imaging and image processing pertinent to radiology of the cardiac and vascular systems
- To understand the general principles and classification of congenital heart disease and the diagnostic features on conventional radiographs
- To comprehend the natural history and anatomical deformities causing central cyanosis
- To differentiate radiological features and causes of cardiac enlargement, including acquired valvular disease
- To identify the typical features of deep venous thrombosis on Duplex ultrasound
- To identify the typical feature of arterial stenosis and femoral artery pseudoaneurysm on Duplex ultrasound
- To analyze and explain the diagnostic evaluation of ischaemic heart disease, including radionuclide imaging and the basics of coronary angiography
- To differentiate the diagnostic features of vasculitis, atheroma, thrombosis and aneurysmal dilatation of arteries and veins
- To understand the radiological features of pericardial disease

### SKILLS

- To perform ultrasound examinations of arteries and veins under supervision
- To plan and to protocol a CT examination of the cardiac and vascular systems and to adapt it to the individual situation under supervision
- To plan and to protocol an MRI examination of the cardiac and vascular systems and to adapt it to the individual situation under supervision
- To perform proper common post-processing tasks for thoracic imaging studies, including multi-planar reformations (MPR), maximum intensity projections (MIP), minimum intensity projections (MinIP), and vessel analysis tools
- To perform femoral artery and venous puncture techniques under supervision
- To treat femoral artery pseudoaneurysm under supervision

## COMPETENCES AND ATTITUDES

- To justify diagnostic imaging examinations and/or interventional procedures of the cardiac and vascular systems under supervision
- To choose the best-suited method for evaluating disorders of the cardiac and vascular systems under supervision
- To communicate with the patient in order to obtain informed consent prior to diagnostic imaging and interventional procedures of the cardiac, vascular and lymphatic systems
- To choose optimal imaging parameters for radiographic, ultrasonographic, CT and MRI examinations of the cardiac and vascular systems under supervision
- To apply techniques to reduce exposure doses for radiographic and CT examinations of the cardiac and vascular systems under supervision
- To supervise and teach technical staff to ensure that appropriate images are obtained
- To report radiographic, ultrasonographic, CT and MRI examinations of the cardiac and vascular systems with respect to common diseases under supervision
- To appreciate own limitations and to identify when it is appropriate to obtain assistance in interpreting and reporting images of the cardiac and vascular systems
- To identify urgent and/or unexpected findings in imaging examinations of the cardiac and vascular systems and to communicate these timely and properly
- To communicate with patients and their relatives in order to explain their imaging findings of the cardiac and vascular systems
- To participate in and to perform under supervision at multi-disciplinary conferences and tumour boards for diseases of the cardiac and vascular systems

## B-I-3 CHEST RADIOLOGY

### KNOWLEDGE

- To describe the anatomy of the respiratory system, heart and vessels, the mediastinum and the chest wall on radiographs, CT and MRI
- To describe normal variants of the respiratory system, heart and vessels, the mediastinum and the chest wall
- To understand the mean exposure doses of chest radiographs and of chest CT examinations
- To understand techniques to reduce exposure doses of chest radiographs and of chest CT examinations
- To describe the principles of digital imaging and image processing pertinent to chest radiology
- To understand the significance of generic signs on chest radiographs and CT

### GENERIC SIGNS ON CHEST IMAGING

- To confidently identify the following structures on postero-anterior (PA) and lateral chest radiographs:
  - » Right upper, middle and lower lobes; left upper and lower lobes; and lingula
  - » Fissures – major, minor and azygos
  - » Airway – trachea, main bronchi, posterior wall of the intermediate bronchus and lobar bronchi
  - » Heart – position of the atria, ventricles, left atrial appendage and the location of the four cardiac valves
  - » Pulmonary arteries – main, right, left and interlobar
  - » Aorta – ascending, arch and descending aorta
  - » Arteries – brachiocephalic (innominate), carotid and subclavian arteries
  - » Veins – superior and inferior vena cava, azygos, left superior intercostal (“aortic nipple”), and left brachiocephalic (innominate) veins
  - » Components of the thoracic skeleton
  - » Mediastinal stripes and interfaces
  - » Aortopulmonary window
  - » Both hemidiaphragms
- To have an in-depth understanding of the significance of the following chest radiography signs:
  - » Silhouette sign – loss of the contour of the heart or diaphragm indicating an adjacent abnormality (e.g. atelectasis of the right middle lobe obscures the right-hand side of the heart’s border)
  - » Air bronchogram – indicates airless alveoli and, therefore, a parenchymal process as distinguished from a pleural or mediastinal process
  - » Air crescent sign – indicates solid material in a lung cavity, often due to a fungus ball, or crescentic cavitation in invasive fungal infection
  - » Cervicothoracic sign – a mediastinal opacity that projects above the clavicles, situated posterior to the plane of the trachea, while an opacity projecting at or below the clavicles is situated anteriorly
  - » Tapered margins – a lesion in the chest wall, mediastinum or pleura may have smooth tapered borders and obtuse angles with the chest wall or mediastinum, while parenchymal lesions usually form acute angles
  - » Gloved finger sign – indicates bronchial impaction, e.g. in allergic bronchopulmonary aspergillosis, or other chronic obstructive processes
  - » Golden sign – indicates lobar collapse with a central mass, often due to an obstructing bronchogenic carcinoma in an adult
  - » Deep sulcus sign on a supine radiograph – indicates pneumothorax
- To describe monitoring and support devices (“tubes and lines”) and to confidently identify them on imaging studies

- To describe the imaging features and the preferred placement of the following devices and lines and to list the complications associated with the malpositioning of each of the following:
  - » Endotracheal tube
  - » Central venous catheter
  - » Swan-Ganz catheter
  - » Nasogastric tube
  - » Chest tube/drain
  - » Intra-aortic balloon pump
  - » Pacemaker and pacemaker leads
  - » Implantable cardiac defibrillator
  - » Left ventricular assistant device
  - » Atrial septal defect closure device (“clamshell device”)
  - » Pericardial drain
  - » Extracorporeal life support cannulae
  - » Intra-oesophageal manometer, temperature probe or pH probe
  - » Tracheal or bronchial stent

---

- To describe the typical chest radiography appearances of pleural effusion on erect, supine and lateral decubitus chest radiographs, and to list four causes of a large unilateral pleural effusion

---

- To describe the imaging features of pleural-based masses with bone destruction or infiltration of the chest wall on a radiograph or chest CT, and to list four likely causes

---

- To describe the imaging features of a unilateral elevation of one hemidiaphragm on chest radiographs and to list five causes (e.g. subdiaphragmatic abscess, diaphragm rupture and phrenic nerve involvement with lung cancer, post-cardiac surgery, eventration)

---

- To describe the imaging features and clinical features of tension pneumothorax

---

- To describe the normal dimensions of the thoracic aorta

---

- To have an in-depth understanding of the Stanford A and B classification of aortic dissection and the implications of the classification for medical versus surgical management

---

- To comprehend the features on radiographs and CT and the differential diagnosis of diffuse interstitial and alveolar lung disease, airways and obstructive lung disease

---

- To differentiate solitary and multiple pulmonary nodules, benign and malignant neoplasms, hyperlucencies and their potential aetiology and evaluation

---

- To differentiate thoracic diseases in immunocompromised patients and congenital lung disease

---

- To analyze and explain disorders of the pulmonary vascular system and great vessels

---

- To understand the diagnostic role of radiographs, radionuclides, CT and MRI in the diagnostic evaluation of disorders of the pulmonary vascular system and great vessels

---

- To differentiate abnormalities of the chest wall, mediastinum and pleura



## SKILLS

- To plan and to supervise the proper acquisition of radiographs, chest radiographs, ventilation/perfusion imaging, thoracic CT, high-resolution chest CT, and the CT pulmonary angiography (CTPA)
- To perform proper positioning of chest radiographs and of chest CT examinations for adults, newborns, infants and children
- To plan and to protocol a CT examination of the chest and to adapt it to the individual situation
- To plan and to protocol an MRI examination of the chest and to adapt it to the individual situation
- To perform proper common post-processing tasks for thoracic imaging studies, including multi-planar reformations (MPR), maximum intensity projections (MIP), minimum intensity projections (MinIP), and vessel analysis tools
- To perform ultrasonographic examinations in the diagnosis
- To perform aspirations of pleural fluid under image-guidance

## COMPETENCES AND ATTITUDES

- To justify diagnostic imaging examinations and/or interventional procedures of the chest
- To choose the best-suited method for evaluating disorders of the chest
- To communicate with the patient in order to obtain informed consent prior to diagnostic imaging and interventional procedures of the chest
- To choose optimal imaging parameters for radiographic, ultrasonographic, CT and MRI examinations of the chest
- To design imaging protocols for CT examinations of the thorax, including the appropriate application of intravenous contrast, spatial and temporal resolution, inspiration/expiration and reconstruction/reformatting techniques
- To apply techniques to reduce exposure doses for radiographic and CT examinations of the chest
- To supervise and teach technical staff to ensure that appropriate images are obtained
- To interpret and report radiographs, chest radiographs, ventilation/perfusion imaging, thoracic CT, high-resolution chest CT and CT pulmonary angiography (CTPA) with respect to common diseases
- To appreciate own limitations and to identify when it is appropriate to obtain assistance in interpreting and reporting images of the chest
- To identify urgent and/or unexpected findings in imaging examinations of the chest and to communicate these timely and properly
- To communicate with patients and their relatives in order to explain their imaging findings of the chest
- To choose optimal biopsy routes and techniques
- To participate in and to perform under supervision at multi-disciplinary conferences and tumour boards for diseases of the chest

## B-I-4 EMERGENCY RADIOLOGY

### INTRODUCTION

The aim of this curriculum in Emergency Radiology (ER) is to ensure that the trainee develops core knowledge, skills, competences and attitudes mainly in imaging and when appropriate, in interventional handling of the various traumatic and non-traumatic emergencies. ER understands itself as a circumstance, condition and somehow disease based subspecialty, which has relevant overlap with organ based as well as with modality based knowledge, skills, competences and attitudes and is mainly embedded in a multidisciplinary context. As a consequence the curriculum will sometimes refer to transferable content from other subspecialty curricula but on the other hand will also equip the trainee for working as a specialist in any branch of radiology. A special focus lies on emergency topics with potentially life threatening conditions and those where fast and precise radiological input may have particular and immediate high impact on best possible outcome and on preparing the trainee as fast as possible to act appropriate and accordingly during night shifts. It also aims to form the basis for further ER Level III subspecialty training.

### KNOWLEDGE

- To describe epidemiological data regarding emergencies
- To understand the common mechanisms of injury including acting forces and their distribution in/ over human bodies
- To understand principles and basic application of estimating emergency severity such as the Injury severity score (ISS) for trauma cases and pain rating scales with regard to the region of pain in non-traumatic cases
- To describe potentially critical legal aspects
- To describe hygiene regulations
- To describe guidelines and corresponding institutional SOPs/algorithms regarding emergency cases
- To describe relevant normal anatomy of the brain, spine, musculoskeletal system, lung, heart, mediastinum, diaphragm, abdominal organs and spaces, genito-urinary tract, venous and arterial system including topographic relationships and cross-sectional appearance
- To describe corresponding common normal variants and abnormalities
- To describe the various radiological modalities and techniques employed in ER including their respective strengths, weaknesses, opportunities and threats regarding ER
- To describe factors and effects of radiation dose as well as techniques for dose reduction
- To describe criteria for good, reasonable/acceptable, poor and insufficient image quality
- To describe the workflow chain of digital imaging, image processing, reading, reporting and the distributing report/images in ER
- To describe the potential risks and benefits of modality dependent contrast media including effects of oral, rectal or vaginal filling

- To describe the various phases of intravenous contrast media application (plain, arterial, portal, delayed, hepatobiliary, urographic) and their respective values according to the clinical problem
- To identify the typical appearance of pericardial effusion, pleural effusion, pneumothorax and free abdominal fluids in enhanced Focused Assessment with Sonography for Trauma (eFAST)
- To describe respective imaging algorithms for various emergency cases
- To describe the relevant pathophysiology, clinical presentation and modality dependent imaging findings of fractures, hypovolemic shock, pneumothorax, pulmonary edema, pericardial tamponade, obstructive and paralytic ileus, hollow organ perforation or anastomotic insufficiency, organ laceration or rupture (heart, liver, spleen, kidney, pancreas), ischemia, embolism, thrombosis, arterial dissection or rupture, urinary calculi, acute cholestasis, acute neurological deficits, severe inflammatory conditions (such as meningitis, acute osteomyelitis, abscesses, severe pneumonia, cholecystitis, appendicitis, ...), ovarian and testicular torsion
- As far as not covered by content above: To describe additional knowledge content of other subspecialty curricula in cases where patients may often present initially to those experts such as musculoskeletal, pediatric, neurological, gynecological /obstetrical and male genitourinary emergencies
- To describe the relevant modality dependent imaging findings of iatrogenic installations regarding tube, drainage or catheter positions
- To describe radiological standard procedures in polytrauma cases, CT under resuscitation and mass casualty incidents
- To describe theory, indications and contraindications for image-guided interventional procedures in emergency settings

## SKILLS

- To assess current guidelines provided by national and international ER and other relevant subspecialty bodies
- To use PACS for interpretation of imaging studies
- To use particular more time effective technical equipment such as dedicated CT workstations for initial interpretation of CT studies
- To properly perform or supervise patient positioning and protocol choice including the application of techniques to reduce dose exposure when appropriate
- To perform eFAST under supervision
- To perform abdominal sonography of emergency cases under supervision
- To perform femoral artery and venous puncture techniques under supervision
- To perform image guided drainage of fluid collections under supervision
- To assist in percutaneous transhepatic drainage of the biliary tract
- To assist in other interventional emergency procedures under imaging guidance, particularly in bleeding control
- To identify modality and body region dependent common imaging findings in emergency cases such as fracture patterns, luxations, cartilage injury, ileus signs, free air and fluids, bleedings, infarctions, embolism
- To classify modality dependent imaging findings to be potentially acute life-threatening, in principal but not immediately life-threatening, severe but not life-threatening or other

- To interpret the relevant modality dependent imaging findings of iatrogenic placement regarding tube, drainage or catheter location
- To assist in image interpretation or therapy of >1500 emergency cases (>500 CR, >100 eFAST, >200 US, >500 CT including >25 polytrauma cases and >25 Triple-rule-outs, >50 MRI, >10 embolisations, >10 PTD, >30 drainage of fluid collections). These cases have to be distributed proportionally over the body regions and the more common pathologies

## COMPETENCES AND ATTITUDES

- To accordingly obtain and interpret relevant clinical information
- To differentiate high-risk from low-risk patients before imaging
- To differentiate and prioritise findings with respect to their urgency after imaging
- To be able to 'screen' as fast as possible for life-threatening findings (e.g. for CT: <10 min after scan start) using an optimised infrastructure and selective image reading in case of high-risk patients
- To understand the respective advantages and disadvantages of different imaging options in emergency cases
- To choose the probably best-suited particular imaging modality and protocol parameters and, if necessary, to proper put imaging techniques into a most appropriate diagnostic pathway considering advances and limitations of the different modalities, diagnostic accuracy and speed, amount of radiation exposure and ethically motivated corresponding individual risk/benefit-analysis with respect to case severity, time-to-diagnose/therapy, patient age and sex
- To communicate as fast as possible and effectively with involved clinicians and supervisory staff
- To participate at multi-disciplinary therapy, morbidity and mortality conferences
- To participate in QA, QM
- To communicate with patients and their relatives with respect to breaking bad news and consent in a multidisciplinary context
- To demonstrate a responsible work ethic
- To appreciate own limitations and to identify when it is appropriate to add further imaging and/or obtain assistance in image interpretation

## B-I-5 GASTROINTESTINAL AND ABDOMINAL RADIOLOGY

### KNOWLEDGE

- To describe the normal anatomy of the abdomen and the main variants including the internal viscera, abdominal organs, omentum, mesentery and peritoneum on conventional radiology, CT, ultrasound and MRI
- To understand the mean exposure doses of abdominal radiographs and of abdominal CT examinations
- To understand techniques to reduce exposure doses of abdominal radiographs and of abdominal CT examinations
- To describe the clinical presentation and natural history of the most common and/or severe diseases of the abdomen, and the principles of their treatment
- To understand normal post-procedure imaging related to previous treatment such as surgery or interventional radiology
- To understand imaging features of abdominal trauma and acute conditions, including perforation, haemorrhage, inflammation, infection, obstruction, ischaemia and infarction on radiographs, ultrasound and CT
- To describe the imaging features and basic clinical features of colon tumours, diverticulitis, inflammatory diseases, colon ischaemia and radiation-induced colitis
- To describe the imaging features and basic clinical features of megacolon, colonic diverticulosis, specific and non-specific colitis, colonic fistula, carcinoma, polyps and postoperative stenosis on an enema
- To describe the imaging features of colonic diverticulosis, diverticulitis, tumour stenosis, ileocolic intussusception, colonic fistula, paracolic abscess, epiploic appendagitis, intra-peritoneal fluid collection, colonic pneumatosis and pneumoperitoneum on CT
- To differentiate imaging features of primary and secondary tumours of the solid abdominal organs and gastrointestinal tract
- To identify imaging features in regard to the stage and extent of tumours, including features that indicate non-resectability
- To understand both the technique and the role of associated examinations like endoscopy, endoscopic ultrasound and nuclear medicine (including SPECT, PET and hybrid imaging)
- To understand radiological manifestations of inflammatory bowel diseases, malabsorption syndromes and infection
- To differentiate the aetiology and imaging signs of chronic liver diseases, including portal hypertension
- To differentiate the major vascular abdominal lesions including arterial diseases, arterial, portal or hepatic venous obstruction and to understand their consequences
- To understand the principles and the main applications of quantification and functional imaging in abdominal diseases, such as quantification of liver fat, iron or fibrosis, tumour perfusion and bowel inflammation
- To describe the rationale and basic principles of diffusion-weighted imaging in abdominal diseases
- To describe the basic principles and standards of post-therapy imaging evaluation (tumour, inflammation)
- To understand the main indications and techniques of interventional radiology as applied to abdominal diseases
- To describe the typical imaging features of a small bowel series and to recognise the various segments of the small bowel and normal findings

## SKILLS

- To recognize proper positioning of abdominal radiographs for adults, newborns, infants and children
- To plan a CT examination of the abdomen and to adapt it to the individual clinical condition in regard to intravenous contrast medium or intraluminal contrast medium application, and contrast phase, with a dose as low as reasonably achievable
- To plan an MRI examination of the upper abdomen and to adapt it to the individual clinical indication in regard to the potential use of intravenous contrast medium, intraluminal contrast medium, contrast medium phase (e.g. arterial phase or delayed imaging), magnetic resonance cholangiopancreatography (MRCP), and quantification of liver fat/iron
- To plan an MRI examinations of the rectum and anal canal and to adapt it to the individual clinical indication
- To plan an MRI examinations of the small bowel and to assist in performing the proper preparation
- To perform contrast medium examinations of the pharynx, oesophagus, stomach, and the small and large bowel
- To perform trans-abdominal ultrasound examinations of the gastrointestinal system, abdominal viscera and their vessels, including Doppler sonography
- To observe contrast-enhanced ultrasonographic studies of the abdominal viscera
- To observe angiography and vascular and non-vascular-interventional techniques in gastrointestinal disease
- To observe the performance of CT colonography
- To perform common post-processing tasks for abdominal imaging studies, including multi-planar reformations (MPR), maximum intensity projections (MIP), minimum intensity projections (MinIP), and vessel analysis tools

## COMPETENCES AND ATTITUDES

- To justify diagnostic imaging examinations and/or interventional procedures of the abdomen and/or gastrointestinal system
- To choose the best method for evaluating disorders of the abdomen and/or gastrointestinal system
- To communicate with the patient in order to obtain informed consent prior to diagnostic imaging and interventional procedures of the abdomen and/or gastrointestinal system
- To choose optimal imaging parameters for radiographic, ultrasonographic, CT and MRI examinations of the abdomen and/or gastrointestinal system
- To apply techniques to reduce exposure doses for radiographic and CT examinations of the abdomen
- To design imaging protocols for CT examinations of the abdomen and gastrointestinal system, including the appropriate application of intravenous and/or intraluminal contrast, spatial and temporal resolution, and inspiration/expiration/breathhold techniques
- To design imaging protocols for MRI examinations of the upper abdomen and gastrointestinal system, including the appropriate application of intravenous and/or intraluminal contrast, spatial and temporal resolution, and inspiration/expiration/breathhold techniques
- To supervise and teach technical staff to ensure that appropriate images are obtained
- To confidently report abdominal radiographs and to propose other imaging techniques in cases of acute abdomen

- To interpret and report abdominal radiographs, ultrasonographic examinations, abdominal CT studies and MRI examinations of the upper abdomen, small bowel, rectum and anal canal
- To report oncological studies according to international standards (RECIST, WHO) applicable to the specific situation
- To appreciate own limitations and to identify when it is appropriate to obtain assistance in interpreting and reporting images of the abdomen and gastrointestinal system
- To identify urgent and/or unexpected findings in imaging examinations of the abdomen and gastrointestinal system and to communicate these in a timely fashion and properly
- To communicate with patients and their relatives in order to explain their imaging findings in the abdomen and gastrointestinal system
- To participate in and to perform under supervision at multi-disciplinary conferences and tumour boards for diseases of the abdomen and gastrointestinal system

## B-I-6

## GYNAECOLOGICAL AND OBSTETRIC RADIOLOGY

## KNOWLEDGE

- To describe the normal anatomy of the female reproductive organs
- To understand the physiological changes affecting normal imaging anatomy of the female reproductive organs throughout the lifespan
- To understand the physiological changes of the female reproductive organs during pregnancy
- To understand the mean exposure doses of radiographs, hysterosalpingography and CT examinations of the female reproductive organs
- To understand techniques to reduce exposure doses of radiographs and CT examinations of the female reproductive organs
- To describe the clinical presentation and natural history of the most common and/or severe diseases of the female reproductive organs
- To understand normal post-procedure imaging of the female reproductive organs related to previous treatment such as surgery or interventional radiology
- To differentiate imaging features of tumours of the female reproductive organs
- To identify imaging features in regard to the stage and extent of tumours of the female reproductive organs, including features that indicate non-resectability
- To understand the imaging features of common disorders associated with pregnancy and delivery
- To understand the main indications and techniques of interventional radiology as applied to the female reproductive organs

## SKILLS

- To perform a transabdominal and, where possible, transvaginal ultrasound in common gynaecological disorders
- To plan a CT examination in patients with common gynaecological disorders and to adapt it to the individual situation with a dose as low as reasonably achievable
- To plan an MRI examination of the female reproductive organs and to adapt it to the individual situation, also in regard to the potential use of intravenous contrast
- To perform imaging examinations for infertility work-up
- To perform proper common post-processing tasks for imaging studies of the female reproductive organs



## COMPETENCES AND ATTITUDES

- To justify diagnostic imaging examinations and/or interventional procedures of the female reproductive organs
- To choose the best-suited method for evaluating disorders of the female reproductive organs
- To communicate with the patient in order to obtain informed consent prior to diagnostic imaging and interventional procedures female reproductive system
- To choose optimal imaging parameters for radiographic, ultrasonographic, CT and MRI examinations of the female reproductive organs
- To apply techniques to reduce exposure doses for radiographic and CT examinations of the female reproductive organs
- To choose the optimally suited imaging modality for pregnant patients
- To design imaging protocols for CT examinations of the female reproductive organs and for staging in patients with tumours of the female reproductive organs
- To design imaging protocols for MRI examinations of the female reproductive organs including the appropriate application of intravenous contrast and spatial and temporal resolution
- To supervise and teach technical staff to ensure that appropriate images of the female reproductive organs are obtained
- To interpret and report radiographs, CT and MRI examinations of patients with disorders of the female reproductive system
- To report oncological studies in patients with tumours of the female reproductive system according to FIGO stage
- To appreciate own limitations and to identify when it is appropriate to obtain assistance in interpreting and reporting images of the female reproductive system
- To identify urgent and/or unexpected findings in imaging examinations of the female reproductive system and to communicate these timely and properly
- To communicate with patients and their relatives in order to explain their imaging findings in disorders of the female reproductive system
- To participate in and to perform under supervision at multi-disciplinary conferences and tumour boards for diseases of the female reproductive system

## B-I-7 HEAD AND NECK RADIOLOGY

The aim of this curriculum in Level I head and neck radiology is to ensure that the trainee develops core knowledge of head and neck diseases that will form the basis for further training (if desired). It will also provide transferable skills that will equip the trainee for working as a specialist in any branch of radiology.

The head and neck imaging curriculum describes:

- The knowledge-based objectives for general head and neck radiology including maxillofacial and dental radiology
- The appropriate technical and communication skills

Physics, radiography and contrast media are generally covered in separate courses, and therefore are not included in this document, but physics and radiography topics specific to head and neck should be included in head and neck radiology training, particularly:

- Positioning/views of radiographs for adults, newborns, infants and children
- Mean exposure doses at skin entrance, KVp, antiscatter techniques
- Principles of digital image processing pertinent to head and neck and maxillofacial dental radiology

### KNOWLEDGE

- To describe the normal anatomy of the head and neck, including paranasal sinuses, the oral cavity, pharynx and larynx, the inner ear, salivary glands, thyroid and parathyroid glands, thoracic inlet, orbit, teeth and the temporomandibular joint
- To recall common congenital lesions of the head and neck, including paranasal sinuses, the oral cavity, pharynx and larynx, the inner ear, orbit, teeth and the temporomandibular joint
- To understand common manifestations of diseases of the eye and orbit including trauma, foreign bodies, inflammation and tumours
- To understand common imaging manifestations of maxillo-facial trauma and tumours and disorders of the teeth
- To understand common imaging manifestations of lesions and abnormal function of the temporomandibular joint
- To understand common imaging manifestations of disorders of the thyroid, parathyroid and salivary glands
- To be aware of the role of radionuclide imaging in disorders of the thyroid and parathyroid glands
- To be aware of the role of radionuclide imaging in the functional evaluation of endocrine abnormalities
- To understand common imaging manifestations of trauma, inflammation, infection and tumours of the paranasal sinuses, oral cavity, larynx and pharynx
- To understand the role of ultrasound- and CT-guided puncture of salivary glands, lymph nodes and the thyroid gland

## SKILLS

- To perform fluoroscopic examinations of the head and neck region, including barium swallows and sialography
- To perform ultrasound examinations of the neck, including thyroid, parathyroid lymph nodes and salivary glands
- To plan a CT examination in patients with common disorders of the head and neck region and to adapt it to the individual situation with a dose as low as reasonably achievable
- To plan an MRI examination of the head and neck region and to adapt it to the individual situation
- To perform proper common post-processing tasks for imaging studies of the head and neck region including multi-planar reformations (MPR) and maximum intensity projections (MIP)
- To observe image-guided interventional techniques of the head and neck region, e.g. fine needle aspiration biopsy of the thyroid gland

## COMPETENCES AND ATTITUDES

- To justify diagnostic imaging examinations and/or interventional procedures of the head and neck
- To choose the best-suited method for evaluating disorders of the head and neck
- To communicate with the patient in order to obtain informed consent prior to diagnostic imaging and/or interventional procedures of the head and neck
- To choose optimal imaging parameters for radiographic, ultrasonographic, CT and MRI examinations of the head and neck
- To apply techniques to reduce exposure doses for radiographic and CT examinations of the head and neck
- To supervise and design imaging protocols for CT examinations of the head and neck, including staging examinations in tumours of the head and neck region and to adapt the examination depending on the imaging findings
- To supervise pre-defined imaging protocols for MRI examinations of the head and neck and to design MRI protocols for common indications
- To supervise and teach technical staff to ensure that appropriate images of the head and neck region are obtained
- To recognize suboptimal image quality and its causes
- To interpret and report radiographs, ultrasonographic examinations, CT studies and MRI examinations for common diseases of the head and neck region
- To report oncological studies of the head and neck region according to international standards (TNM) applicable to the specific situation
- To appreciate own limitations and to identify when it is appropriate to obtain assistance in interpreting and reporting images of the head and neck region
- To identify urgent and/or unexpected findings in imaging examinations of the head and neck region and to communicate these timely and properly
- To communicate with patients in order to explain the imaging findings in the head and neck
- To attend and to conduct under supervision multi-disciplinary conferences and tumour boards for diseases of the head and neck region

## B-I-8 INTERVENTIONAL RADIOLOGY

It is important for radiology trainees to develop a thorough knowledge of the performance and interpretation of diagnostic vascular techniques and an understanding of common interventional procedures, irrespective of whether they specialise in interventional radiology.

### KNOWLEDGE

- To describe the normal anatomy of the arterial and venous system and its relevance to interventional radiology
- To describe typical endovascular approaches to common disorders in interventional radiology
- To describe typical approaches for image-guided biopsy taking
- To describe typical approaches for image-guided placement of drainages
- To describe typical approaches for image-guided ablative techniques
- To understand the risk involved in common interventional techniques
- To understand the use, dosage and administration of local anaesthetics
- To understand the pharmacology, administration and patient supervision in relation to intravenous administration of sedation
- To describe the standard procedure in emergency situations, including resuscitation techniques
- To describe typical catheterisation techniques and the principles of selective catheterisation and embolisation
- To understand the indications for nephrostomy drainage, abscess drainage and pleural drainage

## SKILLS

- To perform basic catheterisation techniques under supervision
- To perform peripheral arteriography under supervision
- To perform image-guided placement of abscess drainages
- To perform image-guided nephrostomy of dilated renal collecting systems
- To perform ultrasound-guided biopsies (at least of superficial structures)
- To perform emergency procedures in life-threatening disorders, including cardio-pulmonary resuscitation

## COMPETENCES AND ATTITUDES

- To justify indications for interventional radiological procedures
- To choose the best-suited approach for an interventional procedure
- To communicate with the patient in order to obtain informed consent prior to an interventional procedures
- To choose optimal imaging parameters for image-guided interventional procedures
- To apply techniques to reduce exposure doses for interventional procedures, both for the patient and for the radiologist and staff
- To supervise and teach technical staff to ensure that appropriate support is provided for interventional procedures
- To safely apply local anaesthetics for pain management in patients undergoing interventional radiological procedures
- To appreciate own limitations and to identify when it is appropriate to obtain assistance in interventional procedures
- To manage and coordinate emergency situations arising from and/or during interventional procedures
- To communicate with patients and their relatives in order to explain the outcome of the interventional procedure
- To participate in and to perform under supervision at multi-disciplinary conferences for patients with potential indications for interventional procedures

## B-1-9 MUSCULOSKELETAL RADIOLOGY

### KNOWLEDGE

- To describe the normal anatomy of the musculoskeletal system
- To be familiar with normal skeletal variants that mimic disease
- To describe common congenital dysplasias of the musculoskeletal system
- To appreciate the value of different imaging techniques in musculoskeletal disorders
- To understand common imaging presentations of trauma involving the skeleton and soft tissue
- To understand the imaging presentation of degenerative disorders of the musculoskeletal system and to appreciate their clinical relevance
- To understand the imaging manifestations of musculoskeletal infection and inflammation
- To understand the imaging manifestations of metabolic diseases, including osteoporosis
- To describe the typical radiographic features of common bone tumours

### SKILLS

- To perform ultrasound examinations of the musculoskeletal system for common musculoskeletal disorders
- To plan a CT examination in patients with common disorders of the musculoskeletal system and to adapt it to the individual situation with a dose as low as reasonably achievable
- To plan an MRI examination of the musculoskeletal system and to adapt it to the individual situation
- To perform proper common post-processing tasks for imaging studies of the musculoskeletal system including multi-planar reformations (MPR) and maximum intensity projections (MIP)
- To perform image-guided application of intraarticular contrast media for MR arthrography or CT arthrography under supervision

## COMPETENCES AND ATTITUDES

- To justify diagnostic imaging examinations of the musculoskeletal system
- To choose the best-suited method for evaluating disorders of the musculoskeletal system
- To communicate with the patient in order to obtain informed consent prior to diagnostic imaging of the musculoskeletal system
- To choose optimal imaging parameters for radiographic, ultrasonographic, CT and MRI examinations of the musculoskeletal system
- To apply techniques to reduce exposure doses for radiographic and CT examinations of the musculoskeletal system
- To design imaging protocols for CT examinations of the musculoskeletal system
- To design imaging protocols for MRI examinations of the musculoskeletal system
- To supervise and teach technical staff to ensure that appropriate images of the musculoskeletal system are obtained
- To interpret and report radiographs, ultrasonographic examinations, CT studies and MRI examinations of the musculoskeletal system
- To appreciate own limitations and to identify when it is appropriate to obtain assistance in interpreting and reporting images of the head and neck region
- To identify urgent and/or unexpected findings in imaging examinations of the musculoskeletal system and to communicate these timely and properly
- To communicate with patients and their relatives in order to explain their imaging findings of the musculoskeletal system
- To participate in and to perform under supervision at multi-disciplinary conferences for diseases of the musculoskeletal system

## B-I-10 NEURORADIOLOGY

### KNOWLEDGE

- To describe normal anatomy and normal variants of the brain, skull, skull base, spine and spinal cord peripheral nervous system
- To describe the normal anatomy of the craniocervical and spinal arterial and venous system and its relevance to interventional neuroradiology
- To describe typical endovascular and percutaneous approaches to common disorders in interventional neuroradiology (brain, skull, skull base and spine/spinal cord)
- To recall common congenital lesions of the brain, skull, skull base, spine, spinal cord and peripheral nervous system
- To understand the rationale for selecting certain imaging techniques, and the use of contrast administration, in diagnosing diseases of the central and peripheral nervous system
- To understand imaging features of stroke, haemorrhage and other common vascular lesions of the brain and spinal cord and to differentiate these from other disorders
- To understand imaging features of traumatic brain injury and spinal trauma and to comprehend their neurological sequelae
- To understand imaging features and differential diagnoses of white matter disease, inflammation and degeneration
- To understand imaging features of benign and malignant tumours of the skull, skull base, brain, spine, spinal cord and cranial and peripheral nerves
- To appreciate the role of nuclear medicine, including PET/PET-CT, in the diagnostic evaluation of disorders involving the central nervous system, skull, skull base, and spine



## SKILLS

- To perform ultrasonographic examinations of the carotid arteries, including Doppler-sonographic studies
- To observe ultrasonographic and Doppler-sonographic studies of intracranial vessels
- To perform basic vascular catheterisation and percutaneous techniques under supervision
- To observe diagnostic and interventional supraaortic digital subtraction angiographies
- To observe diagnostic and interventional spinal digital subtraction angiographies
- To observe image-guided puncture of the spine with and without contrast media application (myelography, diagnostic lumbar puncture)
- To plan CT examinations in patients with common disorders of the brain, skull, skull base, and spine and to adapt them to the individual situation with a dose as low as reasonably achievable, including the decision for or against contrast administration
- To plan MRI examinations in patients with common disorders of the brain, skull, skull base, and spine and to adapt them to the individual situation, including the decision for or against contrast administration
- To perform proper common post-processing tasks for imaging studies of the brain spine/spinal cord and nerve roots, including multi-planar reformations (MPR), maximum intensity projections (MIP) and vessel analysis tools

## COMPETENCES & ATTITUDES

- To justify diagnostic imaging examinations and/or interventional procedures of the brain, skull and spine
- To choose the best-suited method for evaluating disorders of brain, skull and spine
- To communicate with the patient in order to obtain informed consent prior to diagnostic imaging and/or interventional procedures of the brain, skull and spine
- To choose optimal imaging parameters for radiographic, ultrasonographic / Doppler-sonographic, CT and MRI examinations of the brain, skull and spine
- To apply techniques to reduce exposure doses for radiographic and CT examinations of the brain, skull and spine
- To design imaging protocols for CT examinations of the brain, skull and spine
- To design imaging protocols for MRI examinations of the brain, skull and spine
- To supervise and teach technical staff to ensure that appropriate images of the brain, skull and spine are obtained
- To interpret and report radiographs, ultrasonographic / Doppler-sonographic examinations, CT studies and MRI examinations of the brain, skull and spine
- To report oncological studies of the brain, skull and spine
- To appreciate own limitations and to identify when it is appropriate to obtain assistance in interpreting and reporting images of the brain, skull and spine
- To identify urgent and/or unexpected findings in imaging examinations of the brain and spine and to communicate these timely and properly
- To communicate with patients and their relatives in order to explain their imaging findings of the brain, skull and spine
- To participate in and to perform under supervision at multi-disciplinary conferences, neurovascular boards and tumour boards for diseases of the brain, skull and spine

## B-I-11 PAEDIATRIC RADIOLOGY

### KNOWLEDGE

- To describe normal paediatric anatomy and normal variants, with particular relevance to normal maturation and growth
- To understand imaging features of common disease entities specific to the paediatric age group
- To be familiar with principles of establishing a child-friendly environment
- To have an in-depth understanding of the relative values of and indications for ultrasound, CT and MRI in children
- To understand the increased vulnerability of children to ionizing radiation
- To have an in-depth understanding of the ALARA principle and the special requirements for radiation safety and contrast material dosage in relation to body mass for the paediatric population
- To recall common congenital disorders of the different body regions and their respective relevance for the child's further development
- To be familiar with the imaging features of common disorders of the brain and spine in neonates, infants and children, including traumatic brain injury (accidental and non-accidental), congenital disorders of the brain and spine, hypoxic injury to the brain, brain hemorrhage and brain tumours
- To be familiar with the imaging features of common disorders of the chest in the pediatric population including bronchiolitis, pneumonia, pleural effusion, pneumothorax, foreign body aspiration, mediastinal masses, thymus and variants, malformations of the airways and oesophageal atresia
- To be familiar with the imaging features of common disorders of the abdomen including intestinal obstruction, necrotising enterocolitis, blunt trauma, pneumoperitoneum and abdominal masses
- To be familiar with the imaging presentation of various grades of vesico-ureteral reflux and urethral anomalies
- To be familiar with the imaging features of gastro-oesophageal reflux, malrotation, Hirschprung's disease, and anal imperforation
- To be familiar with imaging features of common disorders of the skeletal system in the paediatric population including fractures (accidental and non-accidental), bone dysplasia, tumours, osteomyelitis, joint effusion, Legg-Calvé-Perthes disease and slipped capital femoral epiphysis

## SKILLS

- To perform ultrasound examinations of the head in hydrocephalus, subependymal and intraventricular haemorrhage, periventricular leukomalacia and tumours in newborns and infants under supervision
- To perform ultrasound examinations of the chest for evaluating pleural effusion, chest consolidation and normal thymus in newborns, infants and children under supervision
- To perform ultrasound examinations of the abdomen for hypertrophic pyloric stenosis, acute intestinal intussusception, acute appendicitis, intestinal obstruction and volvulus, inguinal hernia, in newborns, infants and children under supervision
- To perform ultrasound examinations of the abdomen for abdominal and pelvic masses, uretero-hydronephrosis, urolithiasis and nephrocalcinosis and cystic disease of the kidney in newborns, infants and children under supervision
- To perform ultrasound examinations of the pelvis for acute pelvic pain in female infants, children and adolescents under supervision
- To perform ultrasound examinations of the scrotum for acute scrotal pain, scrotal masses in male infants, children and adolescents under supervision
- To perform ultrasound examinations of the hip in congenital hip dysplasia and transient synovitis in newborns, infants and children under supervision
- To perform routine fluoroscopic contrast medium studies of the gastrointestinal system and urinary tract including voiding cysturethrography in newborns, infants and children under supervision
- To plan and to supervise the proper acquisition of radiographs, CT, and MRI in newborns, infants and children
- To perform proper positioning of radiographs in newborns, infants and children
- To plan and to protocol CT examinations in newborns, infants and children and to adapt it to the individual situation with special consideration of radiation protection in the paediatric population
- To plan and to protocol MRI examinations in newborns, infants and children and to adapt it to the individual situation
- To perform proper common post-processing tasks for paediatric imaging studies, including multi-planar reformations (MPR), maximum intensity projections (MIP), minimum intensity projections (MinIP), and vessel analysis tools
- To observe interventional techniques in paediatric radiology, e.g. management of intussusception

## COMPETENCES AND ATTITUDES

- To justify diagnostic imaging examinations in neonates, infants and children
- To choose the best-suited method for evaluating common disorders in the paediatric population
- To communicate with the parents / caretakers in order to obtain informed consent prior to diagnostic imaging in neonates, infants and children
- To choose optimal imaging parameters for radiographic, ultrasonographic / Doppler-sonographic, CT and MRI examinations of neonates, infants and children
- To apply techniques to reduce exposure doses for radiographic and CT examinations of neonates, infants and children
- To design optimized imaging protocols for CT examinations of neonates, infants and children
- To design optimized imaging protocols for MRI examinations of neonates, infants and children
- To supervise and teach technical staff to ensure that appropriate images of neonates, infants and children are obtained
- To interpret and report radiographs, ultrasound examinations, CT studies and MRI examinations of neonates, infants and children in regard to common disorders in this age group
- To appreciate own limitations and to identify when it is appropriate to obtain assistance in interpreting and reporting images of neonates, infants and children
- To identify urgent and/or unexpected findings in imaging examinations of the neonates, infants and children and to communicate these timely and properly
- To communicate with parents / caregivers in order to explain the imaging findings of their children
- To communicate with children and adolescents in an age-appropriate manner in order to explain diagnostic or interventional procedure or imaging findings
- To participate in and to perform under supervision at multi-disciplinary paediatric conferences and paediatric tumour boards

## B-I-12 UROGENITAL RADIOLOGY

### KNOWLEDGE

(SEE ALSO B-I-6 GYNAECOLOGICAL AND OBSTETRIC RADIOLOGY)

- To describe normal anatomy and normal variants of the kidneys, ureters, bladder and urethra
- To describe normal anatomy and normal variants of the retroperitoneum and the male and female pelvis
- To understand the principles of renal function
- To be familiar with typical imaging features of renal parenchymal diseases, including infection and renovascular disease
- To understand contrast medium management in renal failure
- To be familiar with typical imaging features and with the appropriate imaging investigation algorithm of calculus disease
- To understand the imaging features of urinary tract obstruction and reflux
- To understand imaging features and to differentiate tumours of the kidney and urinary tract
- To understand the typical imaging features of renal transplants
- To understand imaging features and differential diagnoses of pathologies of the prostate, seminal vesicles and testes/scrotum
- To be familiar with urogenital emergencies including management

### SKILLS

- To perform transabdominal ultrasound examinations of the urinary tract and testes
- To plan CT examinations in patients with common disorders of the urogenital system and to adapt the examination protocol to the individual situation with a dose as low as reasonably achievable, including the decision for or against contrast administration
- To plan MRI examinations in patients with common disorders of the urogenital system and to adapt the examination protocol to the individual situation, including the decision for or against contrast administration
- To perform proper post-processing tasks for imaging studies of the urogenital system, including multi-planar reformations (MPR) and maximum intensity projections (MIP)
- To perform ascending urethrograms and micturating cysto-urethrograms under supervision

## COMPETENCES AND ATTITUDES

- To justify diagnostic imaging examinations of the urogenital system
- To choose the best-suited method for evaluating disorders of the urogenital system
- To communicate with the patient in order to obtain informed consent prior to diagnostic imaging of the urogenital system
- To choose optimal imaging parameters for radiographic, ultrasonographic / Doppler-sonographic, CT and MRI examinations of the urogenital system
- To apply techniques to reduce exposure doses for radiographic and CT examinations of the urogenital system
- To design imaging protocols for CT examinations of the urogenital system
- To design imaging protocols for MRI examinations of the urogenital system
- To supervise and teach technical staff to ensure that appropriate images of the urogenital system are obtained
- To interpret and report radiographs, ultrasonographic / Doppler-sonographic examinations, CT studies and MRI examinations of the urogenital system
- To report oncological studies of the urogenital system according to international standards (RECIST, WHO) applicable to the specific situation
- To appreciate own limitations and to identify when it is appropriate to obtain assistance in interpreting and reporting images of the urogenital system
- To identify urgent and/or unexpected findings in imaging examinations of the urogenital system and to communicate these timely and properly
- To communicate with patients and their relatives in order to explain their imaging findings of the urogenital system
- To participate in and to perform under supervision at multi-disciplinary conferences and tumour boards for diseases of the urogenital system

## B-I-13 NUCLEAR MEDICINE AS BASIC TRAINING

It is recommended that a three-month period of training in nuclear medicine should be a component of the radiology curriculum during the first three years in order to gain a familiarity with this specialty. To acquire the basic knowledge of nuclear medicine and hybrid imaging techniques and to understand the role of these techniques within the diagnostic imaging algorithms should be an educational priority. This recommended three-months training period by no means implies a full training in nuclear medicine.

### KNOWLEDGE

- To describe basic principles of physics including the basic atomic structure, principles of radioactivity and basic of radioactive decay
- To be familiar with basic principles of the production of radionuclides, manufacturing, desirable characteristics and physiological clearance of radiopharmaceuticals and PET-tracers
- To explain the principles of biological and effective half-life
- To understand the principles of quantification of PET studies including standardized uptake values (SUV)
- To describe the basic physical principles of nuclear medicine imaging technology, including gamma cameras, single photon emission computed tomography (SPECT), and positron emission tomography (PET)
- To understand the basic physical principles of hybrid imaging, including PET-CT, SPECT-CT, and MR-PET
- To be familiar with imaging performance parameters, including uniformity of response, system sensitivity, spatial resolution, spatial linearity, count rate performance, and image quality
- To understand safety aspects in nuclear medicine and hybrid imaging, including patient dosimetry, staff dosimetry, contamination, monitoring, choice of equipment, quality control and safety/risk management

## SKILLS

- To perform radiopharmaceutical administration under supervision for the following isotope imaging studies: bone, renal, ventilation / perfusion (V/Q), thyroid, parathyroid, white cell, cardiac
- To observe nuclear imaging studies with gamma cameras, single photon emission computed tomography (SPECT), and with positron emission tomography (PET), preferably with hybrid imaging technique

## COMPETENCES AND ATTITUDES

- To apply the appropriateness criteria and indications for nuclear medicine and hybrid imaging procedures under guidance of nuclear medicine specialists
- To assist referring physicians in selecting the best-suited nuclear medicine or hybrid imaging examination for common indications
- To communicate with the patient in order to inform them about the procedures and obtain informed consent prior to nuclear medicine or hybrid imaging studies
- To choose optimal imaging protocols for nuclear medicine and hybrid imaging examinations under supervision
- To apply techniques to reduce exposure doses for nuclear medicine and hybrid imaging studies under supervision
- To interpret and report common nuclear medicine and hybrid imaging studies under supervision
- To appreciate own limitations and to identify when it is appropriate to obtain assistance in interpreting and reporting nuclear medicine and hybrid imaging examinations
- To identify urgent and/or unexpected findings in nuclear medicine and hybrid imaging examinations and to communicate these timely and properly
- To communicate with patients and their relatives in order to explain their imaging findings of nuclear medicine studies under supervision
- To participate in multidisciplinary clinical reviews and tumour boards under supervision



## B-I-14

**RADIATION PROTECTION EDUCATION AND TRAINING****KNOWLEDGE**

- To list the sources and properties of ionising radiation
- To list and explain mechanisms of interaction between ionising radiation and matter/tissues
- To list and explain mechanisms of radioactive decay
- To explain the phenomena of X-ray interaction with matter and the consequences for image generation, image quality and radiation exposure
- To list and explain definitions, quantities and units of kerma, absorbed energy dose (Gy), organ and effective doses (Sv), as well as exposure rate and dose rate
- To understand the mechanism of X-ray production
- To list the components of an X-ray unit and explain the process of X-ray generation
- To explain the function of filters and diaphragms
- To list the common analogue and digital detectors, explain their function and their relative pros and cons
- To explain the role of screens (in analogue radiography) and grids and their effect on image quality and exposure
- To describe radiation effects on cells and DNA
- To describe cellular mechanisms of radiation response, repair and cell survival
- To describe radiation effects upon tissues and organs
- To explain differences in radiation response between healthy tissue and tumours as basis for radiation treatment
- To define and explain stochastic, deterministic and teratogenic radiation effects
- To describe types and magnitudes of radiation risk from radiation exposure in medicine
- To describe the basic principles of radiation protection, as outlined by the ICRP (International Commission on Radiological Protection)
- To specify types and magnitudes of radiation exposure from natural and artificial sources
- To describe concepts of dose determination and dose measurement for patients, occupationally exposed personnel and the public
- To explain the nature of radiation exposure and the relevant dose limits for the worker, including organ doses and dose limits for pregnant workers, comforters, careers, and the general public
- To define As Low As Reasonably Achievable (ALARA) and its applicability to diagnostic radiology settings
- To explain the concepts and tools for dose management in diagnostic radiology with regard to adult and paediatric patients
- To explain the factors influencing image quality and dose in diagnostic radiology
- To describe the methods and tools for dose management in diagnostic radiology: radiography, fluoroscopy, CT, mammography, and those for paediatric patients
- To explain the basic concepts of patient dose measurement and calculation for the different modalities in diagnostic radiology
- To describe the key considerations relevant to radiation protection when designing a diagnostic radiology department
- To list diagnostic procedures performed outside the radiology department with relevant radiation protection considerations

- To list expected doses (reference person) for frequent diagnostic radiology procedures
- To explain quantitative risk and dose assessment for workers and the general public in diagnostic radiology
- To define Quality Assurance (QA) in radiology, QA management and responsibilities, outline a QA and radiation protection programme for diagnostic radiology
- To list the key components of image quality and their relation to patient exposure
- To explain the principle of diagnostic reference levels (DRLs)
- To list national and international bodies involved in RP regulatory processes
- To specify the relevant regulatory framework (ordinances, directives, etc.) governing the medical use of ionising radiation in the respective country and the EU
- To specify the relevant regulatory framework governing the practice of diagnostic radiology in the respective country and in the EU
- To understand the effects of poor-quality images

## SKILLS

- To apply radiation physics to optimally select the best imaging modality
- To apply radiation physics to optimise the protocols, using minimal exposure to reach the image quality level needed for the task
- To use the laws of physics to minimise scatter and optimise contrast
- To use the correct terms to characterise exposure in daily radiograph fluoroscope and CT examinations and define organ risk, and estimate the genetic and cancer risk
- To use the technical features of the specific equipment and take advantage of all quality-improving and dose-reducing capabilities while recognising the limits of the machine
- To communicate the radiation risk to the patient at an understandable level, whenever there is a significant deterministic or stochastic risk, or when the patient has a question
- To communicate with the referrer regarding justification, and, if necessary, to suggest a different test
- To apply the three levels of justification in daily practise, with respect to existing guidelines, but also to individual cases (e.g. polymorbidity)
- To optimise imaging protocols by using standard operating procedures (SOPs) and by adapting these to the specific patient's size
- To use specific paediatric protocols, by taking into consideration the physics of small size, but also the elevated risk, vulnerability and specific pathology of each age group
- To choose the best compromise between risk-benefit-ratio, image quality and radiation exposure on a case-by-case basis
- To supervise the use of personal protective equipment
- To support monitoring of the workplace and individuals
- To support exposure assessment, investigation and follow up, health surveillance, and records
- To apply and advise on the use of radiation protection measures in diagnostic radiology (radiography, fluoroscopy-intervention, CT, mammography and paediatric patients)
- To stay within guidance/reference levels in daily practice
- To set up size-specific protocols for high-dose procedures

- To estimate organ doses and effective doses for diagnostic radiology examinations, based on measurable exposure parameters (KAP, DLP)
- To apply standards of acceptable image quality
- To perform retake analyses

## COMPETENCES AND ATTITUDES

- To continuously check image quality in order to recognise and correct technical defects
- To demand the best in image quality, technical innovation and exposure reduction for the lowest cost
- To coordinate the commissioning of new equipment with the other members of the core team (radiographer, medical physicist)
- To develop an organisational policy to keep doses to the personnel as low as reasonably achievable (ALARA)
- To avoid unnecessary radiation exposure during pregnancy (warning signs, questionnaire) by optimising the technique (size and positioning of the x-ray field, gonad shielding, tube-to-skin distance, correct beam filtration, minimising and recording the fluoroscopy time, excluding non-essential projections, avoiding repeat radiographs)
- To find and apply the relevant regulations for any clinical situation in radiology
- To choose the best equipment for the patient spectrum based on the resources available
- To take responsibility for choosing the best imaging modalities for the individual patient (radiography, CT, alternatives such as ultrasound or MRI) by taking into consideration the risk of the disease, patient, age and size, the dose level of the procedure, and exposure of different critical organs
- To consult both the patient and staff on pregnancy related concerns in radiation protection
- To take responsibility for patient dose management in different imaging modalities
- To advise patients on the radiation-related risks and benefits of a planned procedure
- To take responsibility for the justification of radiation exposure for every individual patient, with special consideration for pregnant patients
- To take responsibility for choosing and performing the diagnostic procedure with the lowest dose for a given referrer's request
- To take responsibility for optimising the radiographic technique/protocol used for a given diagnostic procedure based on patient-specific information
- To take responsibility for applying the optimal size-adapted and problem-adapted individual protocol for high-dose procedures (CT, fluoroscopy-intervention)
- To supervise quality control procedures on all equipment related to patient exposure
- To take responsibility for the establishment of formal systems of work (Standard Operating Procedures) for radiation protection
- To take responsibility for organisational issues and implementation of responsibilities and local rules in regard to radiation protection
- To take responsibility for compliance with regulatory requirements concerning occupational and public radiation exposures
- To take responsibility for compliance with ALARA principles concerning occupational and public radiation exposures
- To take responsibility for conforming with patient protection regulations (including diagnostic reference levels, where applicable)

## B-I-15

**PRINCIPLES OF IMAGING TECHNOLOGY &  
MOLECULAR IMAGING****KNOWLEDGE****RADIOGRAPHY**

- To explain the relative value of a radiographic examination for the various organ systems and indication
- To have an in-depth understanding of the physical basis of image formation of conventional X-ray
- To explain the concept of electromagnetic waves
- To describe X-ray production, with emphasis on the effects on dose and image quality of altering kV and mA and on the trade-off between diagnostic quality imaging and minimising the effective dose
- To describe the interaction between X-rays and matter
- To describe the structure, role and function of filters, collimators and grids
- To explain the principles of radiographic image acquisition
- To explain the principles of digital image acquisition / digital radiography
- To list and describe the factors affecting image quality in conventional and digital radiography
- To describe the indications for the use of X-ray contrast media in the study of various organs / organ systems
- To describe the principles of fluoroscopy
- To describe the indications for fluoroscopy including the principles of contrast application and to list optimized protocols
- To list techniques to enhance image quality and to reduce radiation in fluoroscopy
- To describe the principles of soft tissue radiography, e.g. in mammography
- To explain the principles of specimen radiography
- To have an in-depth understanding of dosimetry
- To have an in-depth understanding of radiation biology

**COMPUTED TOMOGRAPHY - CT**

- To explain the relative value of a CT examination for the various organ systems and indications
- To have an in-depth understanding of the physical basis of image formation of computed tomography and of the physics of helical and multidetector CT
- To have a basic understanding of dual-source CT
- To list the major sources of artefacts in CT
- To define the scale of Hounsfield units and to explain the principle of window centre and width
- To list the optimal setting of window centre and width for various organs and tissues
- To list the normal levels of attenuation (in HU) for the various organs and pathological processes in the body
- To describe the principles of optimising sequence protocols for a variety of CT scanner types
- To understand the principles of perfusion imaging with CT

- To understand the principles of CTA protocols, including contrast materials used and reconstruction techniques
- To define CT protocols for the various organs and pathological processes in the body
- To explain the principles of reconstruction algorithms and kernels
- To describe the indications for the use of CT contrast media in the study of various organs / organ systems
- To have a detailed understanding of CT-dosimetry

## MAGNETIC RESONANCE IMAGING - MRI

- To explain the relative value of an MRI examination for the various organ systems and indications
- To explain the fundamentals of MR physics
- To have a basic understanding of the physical basis of image formation in MRI
- To explain the principles of pulse sequences and relaxation times
- To explain the principles of spin echo and gradient echo sequences
- To describe the principles and main diagnostic applications for the most commonly used sequences in MRI, including T2-weighted sequences, T1-weighted sequences, STIR sequences, FLAIR sequences, other inversion recovery sequences, and T2\*- / susceptibility weighted sequences
- To describe the typical appearance of tissues, organs and pathological processes on these MR sequences
- To understand the sequence technology for MR angiography (MRA) including time of flight (TOF) MRA and contrast-enhanced MRA
- To discuss the advantages and disadvantages of different contrast materials used for MRA
- To discuss the differences between time-of-flight, phase contrast, and contrast-enhanced techniques pertaining to MRA
- To discuss advantages and disadvantages of MRA compared with other techniques
- To explain the principles of dynamic contrast-enhanced (DCE) MRI
- To explain the principles of diffusion-weighted imaging (DWI) and diffusion tensor imaging (DTI)
- To have an appreciation of the principles of functional MRI (fMRI) using BOLD contrast
- To outline the principles of spectroscopy using <sup>1</sup>H, <sup>31</sup>P, <sup>13</sup>C
- To describe typical artefacts on MR imaging and to discuss their respective causes
- To describe the indications for the use of MR contrast media in the study of various organs / organ systems
- To explain the absolute or relative contraindications against MR imaging and how to handle MR examination of patients with relative contraindications requiring examination in special coils, etc.
- To explain the safety issues in the MR environment with regard to patients and staff

## ULTRASOUND

- To explain the relative value of an ultrasound examination for the various organ systems and indications
- To describe the nature of ultrasound waves, their propagation, velocity, intensity and the equations that describe them
- To describe the principles of acoustic impedance and to list the tissue properties that determine it
- To describe the frequency of transmission to achieve satisfactory imaging
- To describe the physical principles of the piezoelectric phenomenon

- To list factors that determine the resonance frequency of the piezoelectric element
- To explain the principles of continuous and pulsed emission ultrasound
- To list the factors that focus and unify the ultrasound beam
- To describe the differences between the A, B and TM modes of ultrasound
- To explain the principles of spatial and temporal resolution of ultrasound images as applied to good image formation
- To explain the principles of the Doppler effect and the application of angled beam and direction of flow
- To describe the application of pulsed and continuous wave Doppler and spectral waveform analysis
- To describe the thermal and mechanical biological effects of ultrasound waves, including production of the cavitation phenomenon
- To describe the different types of transducers in ultrasound imaging
- To list the appropriate transducers according to the organs imaged
- To explain the relative value of transcutaneous vs. endoluminal sonography
- To describe criteria for a good ultrasound image
- To describe the major artefacts on ultrasound imaging including reflection, diffusion and speckle and to list their respective causes
- To describe the indications for the use of ultrasound contrast media in the study of various organs / organ systems

## CONTRAST MEDIA

- To understand the molecular structure, pharmacology, classification, dose and side effects of all radiographic, MRI and ultrasound contrast media
- To explain the principles of contrast ultrasound media and the relation between the ultrasound beam and microbubbles
- To explain the principle of ionic and non-ionic contrast agents
- To describe the physiological principles, physical properties, toxic effects, anaphylactoid reaction and biological effects of iodinated contrast media
- To describe the physiological principles, physical properties, toxic effects, anaphylactoid reaction and biological effects of MRI contrast media
- To outline the best contrast material and its optimal use according to the imaging technique and the clinical problem
- To describe the various timing phases of contrast media application and their respective values according to the clinical problem
- To describe the fundamentals of intravascular bolus kinetics and constant rate input
- To describe the physiology of renal excretion of contrast medium
- To describe enhancement curves within renal compartments after injection of contrast agents
- To list concentrations and doses of contrast agents used intravenously
- To define the nephrotoxicity of contrast media
- To list risk factors of contrast media nephrotoxicity

- To identify patients at risk of contrast media nephrotoxicity
- To list methods to reduce the risk of contrast nephrotoxicity
- To describe precautions in diabetics taking metformin and requiring intravascular administration of contrast media
- To list measures to reduce the risk of contrast media nephrotoxicity
- To have an in-depth understanding of nephrogenic systemic fibrosis (NSF) including the definition of NSF, the clinical features and the risk factors
- To describe the use of Gadolinium-based contrast media in patients at risk

## IMAGING INFORMATICS

- To explain the infrastructure of imaging informatics, including Picture Archiving and Communication Systems (PACS), Radiological Information Systems (RIS) and Electronic Patient Records
- To list informatics standards, including DICOM, HL7 and IHE
- To have an understanding of image processing and analysis tools, including 2D and 3D reconstructions, 2D and 3D image analysis, quantitative imaging, image fusion, virtual reality, augmented reality, functional analysis, and computer aided diagnosis
- To explain e-learning tools
- To discuss relevant aspects of teleradiology and telemedicine
- To have an understanding of structured reporting

## SIGNAL PROCESSING AND POST-PROCESSING

- To have a basic understanding of the principles of signal processing
- To describe the principles of linear systems including convolution, Fourier transformation, Nyquist, image restoration, and deconvolution
- To describe the principles of image display
- To have an in-depth understanding of image quality, including noise, contrast, resolution, and noise amplification during processing
- To be familiar with the principles of quantification including ROI analyses, time-activity curves and factorial analysis
- To understand the principles of image processing including edge, detectors, smoothing, segmentation, image reconstruction, image fusion, registration, and display

## MOLECULAR IMAGING

- To have an understanding of basic principles of cell biology and biochemistry including DNA and RNA activity, metabolism, apoptosis and hypoxia
- To have a basic understanding of stem cell migration and stem cell differentiation
- To understand the basic principles of the most commonly used molecular imaging methods, including nuclear medicine (PET, micro-PET, micro-SPECT) and optical imaging (fluorescence, bioluminescence)
- To have a basic understanding of principles of targeted contrast agents

- To have a basic understanding about demand on pharmacology and pharmacokinetics for a diagnostic probe
- To list the most common molecular targets for imaging
- To list the most commonly used tracers in molecular imaging
- To have an appreciation of the methods of molecular imaging, including its potential application to oncology, cardiovascular imaging, neurology and drug delivery
- To have a basic understanding of the strategies of gene therapy, including gene replacement, gene repair and silencing, and of cell therapy
- To have an understanding about chemistry and biotechnology methods relevant for probe development
- To understand PET image analysis and data processing

## SKILLS

- To choose the optimal contrast medium for common clinical indications for all types of imaging studies
- To be able to perform an emergency treatment for adverse reactions to contrast media when required
- To identify patients at risk of contrast media nephrotoxicity
- To take measures to reduce the risk of contrast nephrotoxicity
- To take precautions in diabetics taking metformin and requiring intravascular administration of contrast media
- To take measures to reduce the risk of contrast media nephrotoxicity
- To identify patients at risk to develop NSF
- To choose optimal exposure parameters for radiographic imaging
- To choose optimal acquisition parameters for common CT applications
- To choose optimal MR sequences for common indications for MR imaging
- To choose the appropriate transducer according to the organ imaged
- To choose optimal imaging parameters in ultrasound and Doppler sonography
- To obtain Doppler spectra on the various vessels of the body

## COMPETENCES AND ATTITUDES

- To choose optimal imaging parameters for all imaging technologies
- To make informed purchasing decisions for imaging equipment for a radiological department respecting imaging technology, radiation protection and budget restrictions
- To devise strategies to reduce artefacts on conventional radiography, fluoroscopy, CT, MRI and ultrasound
- To appreciate the effect of the properties of the machine/scanner on image quality and to optimize the image quality for the machine/scanner available for all common imaging indications
- To appreciate the effect of the properties of image recording and display and to optimize the image quality in the available setting for all common imaging indications
- To appreciate the impact that image quality has on clinical performance and to enhance image quality to the best extent possible
- To confidently devise and conduct quality assurance programmes



## B-I-16 COMMUNICATION AND MANAGEMENT

### KNOWLEDGE

- To be familiar with the principles of communicating bad news
- To have an in-depth understanding of the nature, structure and medicolegal aspects of radiological reporting
- To understand the importance of timely communication with referring doctors with regard to imaging reports
- To understand the important role of the radiologist in multidisciplinary meetings and tumour boards
- To know the basic principles of communication in multidisciplinary meetings, including an appreciation of the transfer of knowledge, demonstration of imaging findings, and awareness of treatment consequences
- To understand the basic didactic principles of teaching radiology
- To describe the principles of administration and management as applicable to a clinical imaging department with multidisciplinary staff and high-cost equipment
- To be familiar with the procedures, legalities, critical evaluation processes and priorities required for systems purchase
- To understand the principles of teleradiology and its potential role and legal implications
- To understand the methodology and principles of the clinical audit with honesty and integrity, full agreement and confidentiality
- To understand the concept of measured performance and the comparison with target standards
- To interpret the results of audit measurements, the process of implementing change and the re-measurement of performance
- To understand the limitations of the selection of appropriate target standards
- To describe relevant country-specific legal implications of audits
- To appreciate the concepts of consensus statements from learning bodies and the methodology for sourcing them
- To understand the medico-legal implications of radiological practice
- To understand the concept of perceptual errors
- To be aware of the risk and consequences of missed radiographic diagnoses
- To be familiar with concepts to minimize radiological risk
- To have an in-depth understanding of more common radiological pitfalls
- To be familiar with the concepts of uncertainty and error in radiological practice
- To describe the concept of hindsight bias
- To understand the importance of the comparison with previous examinations
- To be aware of the specific liabilities relating to screening
- To have a basic understanding of health economics

## SKILLS

- To formulate a comprehensive radiological report according to accepted standards
- To use an adequate terminology for the respective clinical question
- To perform cost-benefit and cost-efficiency evaluations for common imaging strategies
- To perform audits of structure, process and outcome
- To teach undergraduate students or other trainees relevant radiological knowledge and skills

## COMPETENCES AND ATTITUDES

- To relate to the patient and their families with respect, honesty and confidentiality
- To be able to explain diagnostic imaging examinations and interventional procedures to the patient and to obtain informed consent
- To be able to explain examination results to patients and/or their families when appropriate
- To properly communicate with referring clinical colleagues
- To distinguish between routine methods of communication, and the necessity for immediate reporting of emergency, life-threatening or unexpected findings
- To timely and adequately communicate urgent or unexpected findings

## B-I-17

**RESEARCH AND EVIDENCE-BASED MEDICINE****KNOWLEDGE**

- To understand the basic elements of scientific methods and evidence-based medicine
- To have an in-depth understanding of design and data analysis for technical and diagnostic performance studies, including the influence of disease prevalence and spectrum on sensitivity, specificity, accuracy, and predictive values as well as the use of ROC analysis in radiological studies
- To understand the statistics necessary for critical assessment of published radiological primary and secondary studies (i.e. meta-analyses, cost-effective analyses)
- To describe basic statistics used in studies comparing treatments (i.e. randomized controlled trials)
- To understand the principles and practice of clinical audit
- To have a basic understanding of didactic methods to teach radiology

**SKILLS**

- To present studies from the radiological literature in departmental meetings
- To perform basic biostatistical tests relevant to the radiological literature
- To perform a focussed literature search of the relevant radiological literature
- To perform clinical audit in a radiological department

**COMPETENCES AND ATTITUDES**

- To appraise the relevant radiological literature in a critical manner
- To plan and conduct research studies under supervision in a methodologically sound manner
- To understand the value and methods of evolving imaging technologies

B-II:  
**LEVEL II  
TRAINING  
(YEARS 4-5)**

# LEVEL II TRAINING (YEARS 4-5)

## INTRODUCTION

---

Level II Training should be interpreted as a continuum of radiology training. During these two years it is envisaged that the trainee should spend approximately 50% of the time in general radiology, with 50% exposure to a maximum of two subspecialty areas. One of these subspecialty areas may remain general radiology.

**The curricular content for Level II Training comprises the following subject areas:**

B-II-1 Breast Radiology

---

B-II-2 Cardiac and Vascular Radiology

---

B-II-3 Chest Radiology

---

B-II-4 Emergency Radiology

---

B-II-5 Gastrointestinal and Abdominal Radiology

---

B-II-6 Gynaecological and Obstetric Radiology

---

B-II-7 Head and Neck Radiology

---

B-II-8 Interventional Radiology

---

B-II-9 Musculoskeletal Radiology

---

B-II-10 Neuroradiology

---

B-II-11 Oncologic Imaging

---

B-II-12 Paediatric Radiology

---

B-II-13 Urogenital Radiology

---

## B-II-1 BREAST RADIOLOGY

### KNOWLEDGE

- To have an in-depth understanding of epidemiological data regarding breast cancer
- To identify major risk factors of breast cancer, including familial-genetic predisposition and previous thoracic radiation therapy
- To understand principles of risk stratification and the indications for genetic counselling
- To appreciate the principles and objectives of population screening
- To be aware of the masking effect of breast density determining a reduced sensitivity of mammography
- To know the relative role of breast density as a risk factor for breast cancer
- To describe the structure and management of a national or regional screening programme (if it exists)
- To identify the risks and benefits of screening to the population and the individual, including those related to subject age, family and personal history
- To understand screening theory and to describe lead time bias, length bias, survival versus mortality rates, prevalence versus incidence screening, definition of lead time and interval cancer rate, overdiagnosis and overtreatment
- To describe the European guidelines for breast cancer screening and diagnosis (<http://www.euref.org/european-guidelines>)
- To know the potential of tomosynthesis in the screening setting for increasing the detection rate and reducing the recall rate
- To describe the principles and techniques used in screening audit, desirable goals for positive predictive value, percentage of stage 0 (ductal carcinoma in situ) and stage I tumours, minimal carcinomas, node positivity, prevalent and incident cancer rates, recall rates, interval cancers, sensitivity, specificity and false-negative rate, and the importance of data collection
- To analyse controversies regarding mammographic screening and related research, including the current debate on the estimate of overdiagnosis/overtreatment
- To describe normal embryology, anatomy and physiology of the breast, axilla and associated structures and to particularly understand changes due to age, lactation, hormonal status, hormone replacement therapy, surgery (including breast reduction/augmentation as well as oncoplastic reconstruction), radiotherapy etc.
- To have an in-depth understanding of benign diseases of the breast and of how these diseases manifest, both clinically and on imaging
- To have an in-depth appreciation of borderline or high-risk breast lesions (those defined to imply an uncertain potential for malignancy), and of their clinical and pathological significance
- To have an in-depth understanding of malignant diseases of the breast, axilla and associated structures, of genetic subtypes, of histological prognostic factors and of the TNM classification
- To know the standardized evaluation of the imaging-based oncologic status of breast cancer patients according to RECIST 1.1 criteria
- To be familiar with cytological and pathological reporting of breast diseases
- To be familiar with the biomolecular classification of breast cancer and to be able to understand the imaging implications of that classification

- To know methods of radiologic-pathologic correlation of breast lesions
- To be familiar with the principles and indications for breast-conserving surgery and sentinel node biopsy
- To describe the indications for neoadjuvant chemotherapy and to understand the clinical and imaging evaluation of response to treatment
- To be familiar with adjuvant therapy options for breast cancer and with methods for surveillance after treatment
- To be familiar with radiation therapy options including methods for partial breast irradiation as well as with typical radiological findings associated with those therapies
- To have an in-depth understanding of the radiological methods for evaluating lesion tumour extent and searching for additional ipsilateral malignant lesions or contralateral malignant lesions, including potential advantages and disadvantages of preoperative MRI
- To have an in-depth understanding of extramammary staging of breast cancer and evaluation of distant metastases
- To be familiar with minimally invasive therapy options for distant metastases
- To appreciate imaging appearance of local recurrence of breast cancer
- To understand the clinical management and radiological evaluation of patients presenting with a palpable breast mass, mastodynia, breast trauma, inflammatory findings, nipple discharge, nipple or skin retraction, nipple thickening and axillary adenopathy
- To understand the imaging work-up and main pathological conditions that can be detected in male patients, children and adolescents, and in pregnant and lactating women
- To have an in-depth understanding of the planning, implementation, supervision and interpretation of all imaging techniques used in breast imaging, as well as potential complications, including indications and contraindications to the various imaging methods
- To have an in-depth understanding of standardized lexicon and categories of breast imaging reporting with reference to lesion, breast, or patient (ACR BI-RADS® or other standardized classification methods)
- To know the advantages, potential indications and limitations of new technologies, such as CAD, tomosynthesis and other digital applications of mammography, elastography, diffusion-weighted MR imaging and MR spectroscopy, different contrast materials for contrast-enhanced MRI, and systems for breast lesion radiofrequency-based excision
- To know indications for tomosynthesis in the clinical setting and the potential of 2D mammograms reconstructed from tomosynthesis dataset
- To have a basic understanding of MR-guided focused ultrasound and other new therapeutic imaging-guided techniques (radiofrequency ablation, cryoablation, electroporation etc) of breast cancer or breast benign diseases
- To know the relative costs of the various imaging examinations utilised in the management of breast diseases
- To appreciate the central role of the multidisciplinary team in planning investigations, treatment and in outcome review for breast cancer patients, being informed about recommendations of the European Parliament in favour of the breast unit model for treating breast cancer (<http://www.europarl.europa.eu/sides/getDoc.do?language=EN&reference=B6-0528/2006>)
- To have an in-depth understanding of the communication principles of breaking news and the psychosocial consequences of doing so improperly
- To understand legal liability in breast imaging

## SKILLS

- To take a detailed history of patients in regard to disorders of the breast and relevant risk factors
- To perform physical examinations of the breast, axilla and associated structures
- To perform radiologic-pathologic correlation of breast lesions
- To supervise the imaging quality of the radiography of surgical specimens and communicate with the surgeon accordingly
- To participate in double reading of screening examination discussing cases of disagreement and getting a feedback after final decision and/or final assessment after recall
- To perform fine needle aspiration at least of cysts which require treatment aspirations
- To perform image-guided fine needle aspiration cytology (free-hand and/or image-guided) or core needle biopsy under ultrasound guidance, including sampling of breast lesions and of suspicious axillary lymphnodes
- To perform mechanical and vacuum-assisted core biopsy (free-hand and/or image-guided) under mammographic stereotactical guidance and under MRI guidance
- To perform image-guided localisation or tomosynthesis
- To perform abscess management

## COMPETENCES AND ATTITUDES

- To choose the best-suited method for evaluating disorders of the breast for a variety of clinical indications
- To justify and optimise all relevant diagnostic imaging examinations and/or interventional procedures of the breast, including minimization of x-ray exposure in mammography and choice of optimal imaging parameters for mammography, ultrasound and MRI of the breast
- To confidently judge the quality of the imaging examinations in breast imaging and to devise strategies to improve image quality
- To supervise and teach technical staff to ensure that appropriate images of the breast are obtained
- To interpret and report mammograms, including those obtained with tomosynthesis, breast ultrasound and breast MRI examinations using a standardized diagnostic categorization system such as the ACR Breast Imaging Reporting and Data System (BI-RADS®); this competence should be acquired by means of performance/reporting (under supervision) of at least 800 mammograms, 500 ultrasound, 50 breast MR studies and 50 interventional procedures during the two years
- To communicate with patients and their relatives in order to explain their imaging findings in disorders of the breast
- To communicate with the patient in order to obtain informed consent prior to interventional procedures of the breast
- To appreciate own limitations and to identify when it is appropriate to obtain assistance in interpreting and reporting images of the breast
- To identify urgent and/or unexpected findings in all types of imaging examinations of the breast and to communicate these timely and properly
- To appreciate and respect the roles and responsibilities of other members of the breast imaging team, e.g. clerical officers, radiographers, nurses, support staff, secretaries etc.
- To appreciate and respect the roles and responsibilities of other members of the multidisciplinary breast care team, being an integral part of the team in planning investigations, treatment and in outcome review
- To perform at multi-disciplinary conferences and tumour boards for diseases of the breast



## B-II-2 CARDIAC AND VASCULAR RADIOLOGY

### KNOWLEDGE

#### ANATOMY & NORMAL VARIANTS

- To have an in-depth knowledge of cardiovascular anatomy in CT
- To describe the major coronary anatomy using 3D CT
- To have an in-depth knowledge of cardiovascular anatomy in MRI
- To have an in-depth knowledge of normal variants of cardiac and coronary artery anatomy, in particular those that may mimic disease

#### CONGENITAL

- To have a basic understanding of the relevant embryological principles of the cardiovascular system
- To describe the imaging features and basic clinical features of congenital heart disease including neonatal heart disease, congenital heart disease in childhood and adult congenital heart disease
- To describe the imaging features of congenital vascular anomalies of the cardiovascular system

#### IMAGE ACQUISITION AND POSTPROCESSING

- To have an in-depth knowledge of the indications, contraindications and potential hazards (especially radiation hazards) of procedures and techniques relevant to cardiovascular disease
- To describe the role of alternative cardiac assessment tools, including SPECT, stress test, echocardiography
- To describe the principles, uses and limitations of nuclear cardiac imaging
- To describe the principles, uses and limitations of intravascular imaging in cardiovascular disorders
- To describe the principles, uses and limitations of cardiac stress testing including exercise stress testing, stress testing in cardiac imaging
- To describe the principles of Cardiac CT acquisition
- To describe the principles of ECG gating for cardiac CT and MRI
- To describe contrast bolus timing as it pertains to cardiac CT and MRI
- To understand axial, multiplanar reconstructions (MPR), maximum intensity projection (MIP) and volume rendering principles as they apply to cardiac CT and MRI
- To describe the principles and techniques of coronary calcification scoring (calcium scoring)
- To understand the limitations of coronary calcification scoring and the epidemiological implications
- To understand the necessary imaging prerequisites and possible risks of Cardiac and vascular MRI in patients with cardiovascular implants

## CORONARY ARTERIES AND MAJOR ARTERIES

- To describe the imaging features and basic clinical features of coronary artery disease, including acute coronary syndromes, myocardial ischaemia, myocardial infarction, post myocardial infarction syndromes, ventricular aneurysms, common and unusual causes of coronary artery disease including various forms of arteritis, hibernating/stunned myocardium
- To describe the imaging presentations of atherosclerosis, including coronary calcification on coronary CTA
- To have a basic pathological and pathophysiological understanding of acquired cardiovascular disease
- To describe the manifestations of cardiovascular disease, including trauma, as demonstrated by conventional radiography, CT, MRI, angiography, radionuclide investigations and ultrasound
- To describe the differential diagnosis relevant to clinical presentation and imaging features of cardiovascular disease
- To describe the imaging features and basic clinical features of diseases of the major vessels, including thoracic aneurysm, popliteal aneurysms, acute and chronic aortic dissection (including classification), Marfan's syndrome, and Takayasu disease
- To describe atherosclerotic disease of the extracranial carotid arteries including grading of carotid artery stenosis by duplex ultrasound, CTA and MRA.
- To describe the imaging features and basic clinical features of diseases of the visceral arteries including acute and chronic mesenteric ischemia
- To describe the imaging features and basic clinical features of peripheral arterial occlusive disease, including the classification of Fontaine, critical limb ischemia, peripheral embolic disease and entrapment syndrome
- To describe the imaging features and basic clinical features of thoracic outlet syndromes

## MYOCARDIUM, PERI- AND ENDOCARDIUM, HEART VALVES

- To describe the imaging features and basic clinical features of cardiac tumours including intracardiac tumours (myxomas, haemangiomas, sarcomas), primary cardiac tumors (myxomas, haemangiomas, sarcomas), secondary/metastatic cardiac tumours
- To describe the imaging features and basic clinical features of cardiomyopathy including acute myocarditis, dilated cardiomyopathy, restrictive and obstructive cardiomyopathy, cardiomyopathy related to systemic disease, infiltrative cardiomyopathy
- To describe the imaging features and basic clinical features of diabetic and renal heart disease
- To describe age- and gender-related cardiac syndromes, including sudden-death syndromes in young men
- To describe the imaging features and basic clinical features of heart valve disease including rheumatic or post-rheumatic valve disease, stenosis and incompetence of cardiac valves, endocarditis, sub- and supravulvar disease, subvalvular apparatus disease
- To describe the pretreatment requisites in case of planned minimal invasive valvular repair (TAVI)
- To describe the imaging features and basic clinical features of pericardial disease
- To describe the imaging features and basic clinical features of athlete's heart
- To have a knowledge of the clinical aspects of cardiac disease including pathophysiological and biochemical correlates
- To describe the principles and practice of screening techniques and risk factors in cardiac disease

## POST-PROCEDURAL CARDIAC AND VASCULAR RADIOLOGY

- To describe the pathophysiology, differential diagnosis and treatment of pseudoaneurysm formation following invasive cardiac procedures
- To describe the role of the varying treatments available for both congenital and acquired cardiac disease, including coronary artery disease and valvular disease
- To describe the typical imaging features and basic clinical features after by-pass grafts, valve replacement, aortic replacements, ventricular surgery, pericardiectomy
- To describe the imaging features and basic clinical features of pericardial disease including acute and chronic pericarditis and malignant cardiac disease
- To describe the typical imaging features and basic clinical features after peripheral bypass graft surgery, peripheral stent placement and surgical patch placement

## SKILLS

- To prepare a patient for cardiac CT including indication, venous access and beta-blocking
- To choose optimal acquisition parameters for cardiac CT
- To choose optimal post-processing tools for cardiac and vascular CT
- To prepare a patient for cardiac MRI including indication, venous access and medication (e.g. stress testing)
- To choose optimal acquisition parameters for cardiac MRI
- To choose optimal post-processing tools for cardiac and vascular CT
- To apply ECG gating for cardiac CT and MRI
- To perform an optimal contrast bolus timing for vascular CT and MRI
- To perform coronary calcification scoring
- To manage procedural complications in the diagnosis and treatment of cardiac disease
- To manage patients undergoing stress testing for cardiac imaging
- To confidently perform ultrasound examinations of arteries and veins
- To independently perform post-processing tasks for cardiac and vascular imaging studies, including multiplanar reformations (MPR), maximum intensity projections (MIP), minimum intensity projections (MinIP), volume rendering tools (VRT) and vessel analysis tools
- To confidently perform femoral artery and venous puncture techniques
- To confidently treat femoral artery pseudoaneurysm
- To perform dynamic examinations to rule out or diagnose thoracic outlet syndromes and entrapment syndromes

## COMPETENCES AND ATTITUDES

- To confidently justify diagnostic imaging examinations (including CT and MRI) and/or interventional procedures of the cardiac and vascular systems
- To confidently choose the best-suited method for evaluating disorders of the cardiac and vascular systems
- To communicate with the patient in order to obtain informed consent prior to diagnostic imaging and interventional procedures of the cardiac, vascular and lymphatic systems
- To choose optimal imaging protocols for radiographic, ultrasonographic, CT and MRI examinations of the cardiac and vascular systems
- To create and apply protocols and standard operating procedures to reduce exposure doses for radiological examinations of the cardiac and vascular systems
- To confidently supervise and teach technical staff to ensure that appropriate images are obtained for all radiological methods pertaining to cardiac and vascular imaging
- To confidently judge the quality of the imaging examinations in cardiac imaging and to devise strategies to improve image quality
- To confidently interpret and report cardiac and Vascular CT for common clinical indications
- To interpret and report cardiac and Vascular CT under supervision for rare clinical indications
- To confidently interpret and report cardiac and Vascular MR for common clinical indications
- To interpret and report cardiac and Vascular MRI under supervision for rare clinical indications
- To confidently report radiographic examinations of the cardiac and vascular systems for common and rare diseases
- To appreciate own limitations and to identify when it is appropriate to obtain assistance in interpreting and reporting images of the cardiac and vascular systems
- To confidently identify urgent and/or unexpected findings in imaging examinations of the cardiac and vascular systems and to communicate these timely and properly
- To communicate with patients and their relatives in order to explain their imaging findings of the cardiac and vascular systems
- To communicate with referring clinicians to discuss radiological findings of the cardiac and vascular systems
- To perform at multi-disciplinary conferences and tumour boards for diseases of the cardiac and vascular systems

## B-II-3 CHEST RADIOLOGY

### KNOWLEDGE

#### NORMAL ANATOMY

- To describe the anatomy of the lobar and segmental bronchi
- To describe the topographic relationships of the hilar vessels and bronchi
- To describe the secondary pulmonary lobule and its component parts
- To describe the terminology for describing the site and size (adenopathy, enlarged lymphnode, normal lymphnode) of mediastinal and hilar lymph nodes
- To describe the normal variants of aortic arch branching, including the common origin of the brachiocephalic and left common carotid arteries (“bovine arch”), and separating the origin of the vertebral artery from the arches
- To confidently identify the following structures on chest CT:
  - » All pulmonary lobes and segments
  - » A pulmonary lobule and associated structures
  - » Fissures – major, minor, azygos and common accessory fissures
  - » Extrapleural fat
  - » Inferior pulmonary ligaments
  - » Airway – trachea, carina, main bronchi, lobar bronchi and segmental bronchi
  - » Heart – left and right ventricles, left and right atria, atrial appendages
  - » Pericardium – including superior pericardial recesses
  - » Pulmonary arteries – main, right, left, interlobar, segmental
  - » Aorta – sinuses of Valsalva, ascending, arch and descending aorta
  - » Arteries – brachiocephalic (innominate), common carotid, subclavian, axillary, vertebral, internal mammary arteries
  - » Veins – pulmonary, superior vena cava, inferior vena cava, brachiocephalic, subclavian, internal jugular, external jugular, azygos, hemi-azygos, left superior intercostal, internal mammary
  - » Oesophagus
  - » Thymus
  - » Normal mediastinal and hilar lymph nodes
  - » Azygo-oesophageal recess

## ALVEOLAR LUNG DISEASES AND ATELECTASIS

- To list the four common causes of segmental consolidation
- To list five of the most common causes of adult (acute) respiratory distress syndrome
- To list four predisposing causes of or associations with organising pneumonia
- To describe the most common causes of bronchiectasis
- To describe the imaging features and basic clinical features of centrilobular, paraseptal and panacinar emphysema
- To describe the imaging findings used to identify surgical candidates for giant bullectomy or lung volume reduction surgery
- To describe the imaging patterns of segmental and lobar consolidation
- To describe the imaging features of partial or complete atelectasis of single or combined lobes on chest radiographs and to list the likely causes
- To describe the imaging features of complete collapse of the right or left lung on a chest radiograph and to list the appropriate causes of the collapse
- To distinguish lung collapse from massive pleural effusion on a frontal chest radiograph
- To recognize the halo sign and its association with a diagnosis of invasive aspergillosis in an immunosuppressed patient
- To describe the imaging features of bronchiectasis on chest radiographs and chest CT
- To describe the HRCT signs of small airways disease and to differentiate between the direct signs (tree-in-bud, centrilobar changes) of exudative bronchiolitis and the indirect signs (mosaic pattern, air-trapping) of obliterative bronchiolitis (bronchiolitis obliterans)
- To describe the typical imaging patterns and basic clinical features of cystic fibrosis
- To describe the typical imaging patterns of tracheal and bronchial stenoses and to list the most common causes
- To describe the typical imaging patterns and basic clinical features of centrilobular emphysema on chest radiographs and CT
- To recognize a unilateral hyperlucent lung on chest radiographs or chest CT and to list an appropriate differential diagnosis
- To recognize the effects of various pathological processes on the component parts of the pulmonary lobule, as seen on high-resolution CT (HRCT)
- To describe the pathophysiology of the following imaging patterns:
  - » Ground glass opacity and lung consolidation
  - » Linear and reticular pattern
  - » Nodular pattern
  - » Honeycombing pattern
  - » Mosaic attenuation pattern
  - » Air trapping
  - » Cysts and cystlike structures
  - » Centrilobular opacities and tree-in-bud
  - » Crazy-paving pattern
- To describe the typical imaging features of thickening of the interlobular septa and the possible causes

## SOLITARY AND MULTIPLE PULMONARY NODULES

- To describe the definitions of a solitary pulmonary nodule and a pulmonary mass
- To list the most common causes of a solitary pulmonary nodule, cavitary pulmonary nodules and multiple pulmonary nodules
- To describe the strategy for managing a solitary pulmonary nodule detected incidentally or at screening
- To have an in-depth understanding of the roles of contrast-enhanced CT and integrated PET-CT in the evaluation of a solitary pulmonary nodule
- To understand the features that indicate benignity of a solitary pulmonary nodule and their limitations
- To describe the complications of percutaneous lung biopsy and their frequency
- To describe the indications for chest tube placement as a treatment for pneumothorax related to percutaneous lung biopsy

## BENIGN AND MALIGNANT NEOPLASMS OF THE LUNG

- To list the four major histological types of bronchogenic carcinoma, and the difference in treatment between non-small-cell and small-cell lung cancer
- To describe the TNM classification for staging non-small-cell lung cancer, including the components of each stage
- To identify abnormal contralateral mediastinal shift on a post-pneumonectomy chest radiograph and to list two possible aetiologies for the abnormal shift
- To describe the acute and chronic radiographic and CT appearance of radiation injury in the thorax (lung, pleura, pericardium) and to identify the temporal relationship with radiation therapy
- To have an in-depth understanding of the roles of CT and MRI in lung cancer staging
- To describe the role of positron emission tomography (PET) and integrated PET-CT in lung cancer staging
- To describe the manifestations and the role of imaging in thoracic lymphoma
- To list the four most common extrathoracic metastatic sites for non-small-cell lung cancer and for small-cell lung cancer

## THORACIC DISEASE IN IMMUNOCOMPETENT, IMMUNOCOMPROMISED AND POST-TRANSPLANT PATIENTS

- To describe the radiological manifestations of pulmonary mycobacterial infections on a radiograph and on CT
- To list the various types of pulmonary aspergillosis, to understand that they form part of a continuum, and to recognise these entities on chest radiographs and chest CT
- To describe the major categories of disease-causing chest radiography or chest CT abnormalities in the immunocompromised patient
- To list two typical infections and two typical neoplasms in patients with AIDS and to describe the imaging features on chest radiography and chest CT
- To describe the typical imaging features and basic clinical features of Pneumocystis jiroveci pneumonia
- To list the three most important aetiologies of hilar and mediastinal adenopathy in patients with AIDS

- To describe the relevant differential diagnoses for widespread consolidation in an immunocompromised host
- To describe the typical imaging features and basic clinical features of post-transplant lymphoproliferative disorders
- To describe the typical imaging features and basic clinical features of graft-versus-host disease

## CONGENITAL LUNG DISEASE

- To describe the typical imaging features and basic clinical features of pulmonary venolobar syndrome (scimitar syndrome)
- To describe the typical imaging features and basic clinical features of intralobar pulmonary sequestration and cystic adenomatoid malformation
- To describe the typical imaging features and basic clinical features of bronchial atresia on a chest radiograph and chest CT, and to list the most common lobes of the lungs in which it occurs

## PULMONARY VASCULAR DISEASE

- To list five of the most common causes of pulmonary artery hypertension and to describe the typical signs on chest radiography and chest CT
- To understand the role of CT pulmonary angiography (CTPA), MRI/MRA and lower extremity venous studies in the evaluation of a patient with suspected venous thromboembolic disease, including the advantages and limitations of each test
- To describe the typical imaging features of enlarged pulmonary arteries on a chest radiograph and to distinguish them from enlarged hilar lymph nodes
- To describe the typical imaging features and basic clinical features of acute and chronic lobar and segmental pulmonary emboli on CT angiography
- To describe the typical imaging features of vascular redistribution seen in raised pulmonary venous pressure

## AIRWAYS AND OBSTRUCTIVE LUNG DISEASE

- To describe the typical imaging features and basic clinical features of bronchiectasis
- To list the typical imaging features of air trapping
- To describe the typical imaging features and basic clinical features of emphysema and the various patterns to include centrilobular, bullous and paraseptal emphysema
- To describe the typical imaging of tracheal abnormalities, including tracheomalacia, tracheal stenosis, and tracheobronchomegaly



## INTERSTITIAL LUNG DISEASE

- To describe the imaging patterns of interstitial lung disease on chest radiographs according to whether the pattern is predominantly in the upper, mid or lower zone; or shows central or peripheral predominance
- To describe typical imaging patterns of interstitial lung disease on chest radiographs including lung consolidation, ground glass opacities, nodular patterns, reticular patterns, cystic patterns and widespread septal lines
- To describe typical imaging patterns of interstitial lung disease on HRCT according to whether the pattern is predominantly in the upper, mid or lower zone; or shows perihilar or subpleural predominance; or shows a vascular or perivascular airway, a lymphatic or perilymphatic or an interstitial distribution
- To describe typical imaging patterns of interstitial lung disease on HRCT including septal thickening / nodularity, ground glass opacity, reticular pattern, honeycombing, nodular pattern, air space consolidation, tree-in-bud pattern, "crazy-paving" pattern, cyst and cyst-like pattern

## PLEURA AND THE DIAPHRAGM

- To describe the typical appearance of pleural effusion on ultrasound
- To describe the typical imaging features of pneumothorax on an upright and supine chest radiographs
- To describe the typical imaging features and basic clinical features of malignant mesothelioma
- To describe the imaging features related to heart failure including pleural effusions, vascular redistribution on erect chest radiographs, interstitial and alveolar oedema
- To define the terms "asbestos-related pleural disease" and "asbestosis", and to describe the respective imaging findings
- To describe the imaging features and basic clinical features of progressive massive fibrosis and conglomerate masses secondary to silicosis and coal worker's pneumoconiosis
- To describe the imaging features of various forms of pleural calcification on a chest radiograph or chest CT and its association with asbestos exposure, old TB, old empyema, or old haemothorax
- To describe the imaging features of diffuse pleural thickening and to list four causes
- To describe the imaging features of split pleura sign in empyema

## MEDIASTINAL AND HILAR DISEASE

- To list the most common causes of an anterior mediastinal mass and to confidently identify a mass in the anterior mediastinum on chest radiographs, chest CT and chest MRI
- To list the three most common causes of a middle mediastinal mass and to confidently identify a mass in the middle mediastinum on chest radiographs, chest CT and chest MRI
- To list the most common causes of a posterior mediastinal mass and to confidently identify a mass in the posterior mediastinum on chest radiographs, chest CT and chest MRI
- To list and describe the most common causes of bilateral hilar lymph node enlargement
- To list and describe the most common causes of "egg-shell" calcified lymph nodes in the chest
- To list and describe the most common causes of a mass arising in the thymus

- To describe the typical imaging features, basic clinical features and common associations of thymoma
- To list and describe the three types of malignant germ cell tumour of the mediastinum
- To describe the mechanisms and signs of pneumomediastinum
- To describe the imaging appearances of normal vessels or vascular abnormalities that may mimic a solid mass
- To describe the imaging features of mediastinal and hilar lymphadenopathy on chest radiographs, chest CT and chest MRI
- To describe the imaging signs of a benign cystic teratoma
- To describe the imaging signs of an intrathoracic thyroid mass
- To describe the imaging features of cystic mediastinal masses and to describe the differential diagnoses of a bronchogenic pericardial, thymic or oesophageal duplication cyst

## THORACIC AORTA AND THE GREAT VESSELS

- To describe the significance of a right aortic arch with mirror image branching versus an aberrant subclavian artery
- To have an in-depth understanding of the advantages and disadvantages of CT, MRI/MRA and trans-oesophageal echocardiography in the evaluation of the thoracic aorta
- To define the terms “aneurysm” and “pseudoaneurysm” of the aorta
- To describe the imaging features and basic clinical features and to distinguish each of the following on chest CT and chest MRI: aortic aneurysm, aortic dissection, aortic intramural haematoma, penetrating atherosclerotic ulcer, ulcerated plaque, ruptured aortic aneurysm, sinus of Valsalva aneurysm, subclavian or brachiocephalic artery aneurysm, aortic coarctation, aortic pseudocoarctation, and cervical aortic arch
- To describe the imaging features of the two standard types of right aortic arch and double aortic arch on chest radiographs, chest CT and chest MRI
- To describe the imaging features of an aberrant subclavian artery on chest CT
- To describe the imaging features seen in arteritis of the aorta on chest CT and chest MRI

## CHEST TRAUMA

- To list three common causes of abnormal lung opacity following trauma on chest radiographs or chest CT
- To list the three most common causes of pneumomediastinum following trauma
- To describe the imaging features of a widened mediastinum on chest radiographs taken for trauma and to list the possible causes (including aortic/arterial injury, venous injury, fracture of sternum or spine)
- To describe the indirect and direct signs of aortic injury on contrast-enhanced chest CT
- To describe the imaging features and basic clinical features and to understand the significance of chronic traumatic pseudoaneurysm on chest radiographs, chest CT or chest MRI
- To describe the imaging features of fractured ribs, clavicle, spine and scapula on chest radiographs or chest CT
- To describe the imaging features of an abnormally positioned diaphragm or loss of definition of a diaphragm on chest radiographs following trauma and the association with a ruptured diaphragm
- To describe the imaging features of a pneumothorax and pneumomediastinum following trauma on chest radiographs

- To describe the imaging features of a cavitory lesion following trauma on chest radiographs or chest CT and to describe the association with laceration and pneumatocele formation, haematoma or abscess secondary to aspiration
- To describe the imaging features and to distinguish between pulmonary contusion, laceration and aspiration

## POSTOPERATIVE CHEST

- To identify normal postoperative findings and complications of the following procedures on chest radiographs, chest CT and chest MRI:
  - » Wedge resection mastectomy, lobectomy
  - » Pneumonectomy
  - » Coronary artery bypass graft surgery
  - » Cardiac valve replacement
  - » Aortic graft
  - » Aortic stent
  - » Transhiatal oesophagectomy
  - » Lung transplant
  - » Heart transplant
  - » Lung volume reduction surgery

## SKILLS

- To prepare a patient for chest CT including indication, venous access and beta-blocking
- To choose optimal acquisition parameters for chest CT
- To choose optimal post-processing tools for chest CT
- To manage procedural complications in the diagnosis and treatment of chest disease
- To design and optimize CT protocols and to adapt these protocols to evaluate each of the following, taking into account the patient's age:
  - » Thoracic aorta and great vessels
  - » Superior vena cava and brachiocephalic vein stenosis or obstruction
  - » Pulmonary embolism
  - » Diffuse lung disease
  - » Tracheobronchial tree
  - » Bronchiectasis
  - » Small airway disease
  - » Lung cancer staging
  - » Oesophageal cancer staging
  - » Superior sulcus tumour
  - » Pulmonary metastases
  - » Pulmonary nodule on a radiograph
  - » Shortness of breath
  - » Haemoptysis
- To confidently perform a radiological staging of bronchogenic cancer

- To perform the following imaging-guided transthoracic interventions under appropriate supervision, to understand the indications and contraindications, and to manage the complications:
  - » Paracentesis and drainage of pleural effusions
  - » Percutaneous lung biopsy
  - » Paracentesis of mediastinal and pericardial fluid collections
  - » Drainage of refractory lung abscess
- To apply inspiratory and expiratory imaging depending on the clinical indication
- To independently perform post-processing tasks for chest imaging studies, including multi-planar reformations (MPR), maximum intensity projections (MIP), minimum intensity projections (MinIP), volume rendering tools (VRT) and vessel analysis tools

## COMPETENCES AND ATTITUDES

- To confidently justify diagnostic imaging examinations (including CT and MRI) and/or interventional procedures of the chest
- To confidently choose the best-suited method for evaluating disorders of the chest
- To communicate with the patient in order to obtain informed consent prior to diagnostic imaging and interventional procedures of the chest
- To choose optimal imaging protocols for radiographic, ultrasonographic, CT and MRI examinations of the chest
- To create and apply protocols and standard operating procedures to reduce exposure doses for radiological examinations of the chest
- To confidently supervise and teach technical staff to ensure that appropriate images are obtained for all radiological methods pertaining to chest imaging
- To confidently judge the quality of the imaging examinations in chest imaging and to devise strategies to improve image quality
- To confidently interpret and report chest CT for common clinical indications
- To interpret and report chest CT under supervision for rare clinical indications
- Making a specific diagnosis of interstitial lung disease (ILD) when HRCT appearances are characteristic
- To confidently interpret and report chest MRI for common clinical indications
- To interpret and report chest MRI under supervision for rare clinical indications
- To confidently report radiographic examinations of the chest for common and rare diseases
- To appreciate own limitations and to identify when it is appropriate to obtain assistance in interpreting and reporting images of the chest
- To confidently identify urgent and/or unexpected findings in imaging examinations of the chest and to communicate these timely and properly
- To communicate with patients and their relatives in order to explain their imaging findings of the chest
- To communicate with referring clinicians to discuss radiological findings of the chest
- To perform at multi-disciplinary conferences and tumour boards for diseases of the chest

## B-II-4 EMERGENCY RADIOLOGY

### KNOWLEDGE

- To have an in-depth understanding of epidemiological data regarding emergency pathologies
- To have an in-depth understanding of the common mechanisms of injury including acting forces and their distribution in/ over human bodies
- To have an in-depth understanding of principles and basic application of estimating emergency severity such as the Injury severity score (ISS) for trauma cases and pain rating scales with regard to the region of pain and clinical appearance in non-traumatic emergencies
- To have an in-depth understanding of legal issues
- To have an in-depth understanding of hygiene regulations
- To have an in-depth understanding of guidelines and corresponding institutional SOPs/algorithms regarding emergency cases
- To have an in-depth understanding of the various radiological modalities and techniques employed in ER including their respective strengths, weaknesses, opportunities and threats regarding ER
- To have an in-depth understanding of factors and effects of radiation dose as well as techniques for dose reduction
- To have an in-depth understanding of good, reasonable/acceptable, poor and insufficient image quality
- To have an in-depth understanding of the workflow chain of digital imaging, image processing, reading, reporting and the distributing report/images in ER
- To have an in-depth understanding of the potential risks and benefits of modality dependent contrast media including effects of oral, rectal or vaginal filling
- To have an in-depth understanding of the various phases of intravenous contrast media application (plain, arterial, portal, delayed, hepatobiliary, urographic) and their respective values according to the clinical problem
- To have an in-depth understanding of respective imaging algorithms for various emergency cases
- To have an in-depth understanding of the relevant modality dependent imaging findings of iatrogenic installations regarding tube, drainage or catheter positions
- To have an in-depth understanding of radiological standard procedures in polytrauma cases, CT under resuscitation and mass casualty incidents
- To have an in-depth understanding of theory, indications and contraindications for image-guided interventional procedures in emergency settings

## ANATOMY

- To describe and have an in-depth understanding of relevant normal anatomy of the brain, spine, musculoskeletal system, lung, heart, mediastinum, diaphragm, abdominal organs and spaces, genito-urinary tract, venous and arterial system including topographic relationships and cross-sectional appearance
- To describe and have an in-depth understanding of corresponding common normal variants and abnormalities
- To describe rare normal variants and abnormalities

## CENTRAL NERVOUS SYSTEM AND BRAIN

- To describe the imaging features and basic clinical features of skull fractures
- To describe the imaging features and basic clinical features of intracranial haemorrhages (subdural, epidural, subarachnoidal, parenchymal)
- To describe the imaging features and basic clinical features of parenchymal injuries (cortical contusion, diffuse axonal injury, deep gray matter injury, brainstem injury)
- To describe the imaging features and basic clinical features of extra- and intracranial vascular injuries
- To describe the imaging features and basic clinical features of penetrating injuries
- To describe the imaging features and basic clinical features of increased intracranial pressure and herniation syndromes
- To describe the imaging features and basic clinical features of arterial cerebral infarction (including the description of particular technical issues such as MR-DWI, MR-perfusion, MRA, CE-MR, TOF, CT-perfusion, CTA)
- To describe the imaging features and basic clinical features of central nervous system infections (meningitis, encephalitis, abscess/cerebritis, subdural empyema, spinal epidural abscess, osteomyelitis/discitis)
- To describe the imaging features and basic clinical features of dural sinus thrombosis

## FACE AND SKULL

- To describe the imaging features and basic clinical features of facial fractures (orbital blow-in and blow-out fractures, nasal fractures, naso-orbital-ethmoid fractures, frontal fractures, maxillary fractures, dentoalveolar fractures, Le-Fort fractures, mandible fractures)
- To describe the imaging features and basic clinical features of orbital injuries (post bulbar emphysema and haemorrhage)
- To describe the imaging features and basic clinical features of ocular injuries (rupture, laceration, lens dislocation, vitreous haemorrhage, subchoroidal haemorrhage)
- To describe the imaging features and basic clinical features of trauma to the larynx, pharynx and upper oesophagus
- To describe the imaging features and basic clinical features of orbital, epidural, subdural or other abscesses/empyemas
- To describe the imaging features and basic clinical features of infections of the paranasal sinuses (acute, fungal, chronic sinusitis, complications)

- To describe the imaging features and basic clinical features of infections of the suprahyoid neck (retropharyngeal and paravertebral abscess, tonsillitis and peritonsillar abscess, odontogenic infections, submandibular and sublingual abscess, parotitis, sialoadenitis, cervical necrotizing fasciitis)
- To describe the imaging features and basic clinical features of acute infections of the infrahyoid neck (epiglottitis, lymphadenitis, jugular thrombophlebitis)
- To describe the imaging features and basic clinical features of external, internal ear infection and mastoiditis (cholesteatoma, apical petrositis)
- To describe the imaging features and basic clinical features of orbital infections and optic neuritis

## SPINE

- To describe the evaluation criteria of low-risk and high-risk patients and of patients with neurological deficits (such as prediction rules, Nexus, CCR)
- To describe the imaging features and basic clinical features of spinal/plexus trauma (spinal cord contusion, spinal epidural hematoma, nerve root avulsion, plexus injuries)
- To describe the assessment of instability of fractures
- To describe and have an in-depth understanding of different mechanisms of injury such as hyperextension/hyperflexion injury including the description of frequently associated injuries
- To describe the imaging features and basic clinical features of different vertebral injuries (occipital condyle fracture, Jefferson burst fracture, atlanto-axial rotary fixation, Hangman's fracture, whiplash injury, wedge compression, burst compression, flexion tear drop fracture, bilateral facet dislocation, chance fracture, complex fracture, pathological fracture, injuries to intervertebral disks)
- To describe the imaging features and basic clinical features of disc herniation
- To describe the imaging features, basic clinical features and common causing pathogens of infections (osteomyelitis, discitis, spondylodiscitis, epidural abscess)

## CHEST, CARDIO-VASCULAR

- To describe the evaluation criteria of low-risk and high-risk patients and of patients with neurological deficits (such as prediction rules, Nexus, CCR)
- To describe the imaging features and basic clinical features of chest trauma (rib fractures, sternal and manubrial fractures, hemothorax, pneumothorax, pneumomediastinum, pulmonary contusion/laceration/hematoma, pneumatocele, tracheal and bronchial injury, oesophageal injury, diaphragm injury)
- To describe the imaging features and basic clinical features of acute pulmonary infections including the various etiologies and causing pathogens as well as aspiration pneumonia
- To describe the imaging features and basic clinical features of airway foreign bodies
- To describe the imaging features and basic clinical features of severe obstructive airway disease
- To describe the imaging features and basic clinical features of ARDS
- To describe the imaging features and basic clinical features of emergencies of the heart (myocardial infarction, myocardial laceration or contusion, pericardial effusion or tamponade, pericardial laceration, pneumopericardium, cardiac valve injury, endo- and myocarditis)

- To describe the imaging features and basic clinical features of aortal emergencies (thoracic aortic trauma, supra-aortic injuries including carotid and vertebral injuries, aortic dissection, aortic aneurysms, aortitis)
- To describe the imaging features and basic clinical features of pulmonary edema including the various etiologies
- To describe the imaging features and basic clinical features of thromboembolic disease including the fat embolism syndrome
- To describe and have an in-depth understanding of the triple rule out concept

## ABDOMEN

- To describe the imaging features and basic clinical features of hemoperitoneum and intraperitoneal fluids
- To describe the imaging features and basic clinical features of retroperitoneal haemorrhage
- To describe the imaging features and basic clinical features of intraperitoneal and retroperitoneal gas collections
- To describe the imaging features and basic clinical features of active arterial extravasation
- To describe the imaging features and basic clinical features of organ injuries (liver, spleen, adrenal, kidney, pancreas, gallbladder, bowel)
- To describe the imaging features and basic clinical features of abdominal wall injuries
- To describe the imaging features and basic clinical features of aortic and major vessel trauma
- To describe the imaging features and basic clinical features of emergencies related with the peritoneal cavity (peritonitis, abdominal abscess, insufficient bowel anastomosis, hollow organ perforation, ascites)
- To describe the imaging features and basic clinical features of liver and biliary tract including obstructive and non-obstructive jaundice and cholecystitis
- To describe the imaging features and basic clinical features of pancreatitis
- To describe the imaging features and basic clinical features of the urinary tract (urinary stones, infection, pyelonephritis, renal abscess, renal infarction)
- To describe the imaging features and basic clinical features of adrenal haemorrhage
- To describe the imaging features and basic clinical features of non-traumatic emergencies of the gastrointestinal tract (gastrointestinal haemorrhage, bowel obstruction, bowel perforation, bowel infarction, omental infarction, appendicitis, diverticulitis, infectious enteritis and colitis, epiploic pseudo-appendicitis, inflammatory bowel disease, Crohn's disease, ulcerative colitis, abdominal compartment syndromes)

## GYNECOLOGY / OBSTETRICS

- To describe the imaging features and basic clinical features of fetoplacental trauma
- To describe the imaging features and basic clinical features of ovarian torsion
- To describe the imaging features and basic clinical features of pelvic inflammatory disease and abscesses
- To describe the imaging features and basic clinical features of acute abdominal disease in pregnancy
- To describe the imaging features and basic clinical features of major and minor trauma in pregnancy
- To describe the imaging features and basic clinical features of ectopic pregnancy



## MALE GENITOURINARY

- To describe the imaging features and basic clinical features of urethral and penile trauma
- To describe the imaging features and basic clinical features of urethral stones and foreign bodies
- To describe the imaging features and basic clinical features of scrotal and testicular trauma
- To describe the imaging features and basic clinical features of testicular torsion
- To describe the imaging features and basic clinical features of epididymitis and orchitis
- To describe the imaging features and basic clinical features of infarction
- To describe the imaging features and basic clinical features of scrotal abscess
- To describe the imaging features and basic clinical features of Fournier's gangrene

## PELVIS

- To describe and classify the imaging features and to describe basic clinical features of pelvis ring fractures and disruptions
- To describe and classify the imaging features and to describe basic clinical features of isolated fractures without pelvis ring involvement
- To describe the imaging features and basic clinical features of bladder injury
- To describe the supportive interventional procedures in bleeding control

## EXTREMITIES (INCLUDING SHOULDER AND HIP)

- To describe and classify the imaging features and to describe basic clinical features of fractures including stress and insufficiency fractures
- To describe and classify the imaging features and to describe basic clinical features of luxations
- To describe and classify the imaging features and to describe basic clinical features of chondral and osteochondral lesions
- To describe and classify the imaging features and to describe basic clinical features of ligamentous tears or ruptures
- To describe and classify the imaging features and to describe basic clinical features of meniscal or labral tears
- To describe the imaging features and basic clinical features of tendon or muscular injuries
- To describe the imaging features and basic clinical features of acute inflammatory diseases
- To describe the imaging features and basic clinical features of avascular necrosis
- To describe the imaging features and basic clinical features of acute compartment syndromes

## PEDIATRIC, INTERVENTIONAL, MUSCULOSKELETAL AND OTHERS

- As long as not mentioned so far: To describe the imaging features and basic clinical features as provided in the corresponding emergency sections of the respective subspecialty curricula
- As long as not mentioned so far: To describe the interventional procedures as provided in the corresponding emergency sections of the respective subspecialty curricula

## SKILLS

- To use and optimise time effective technical equipment such as dedicated CT workstations for initial interpretation of CT studies
- To perform eFAST
- To perform abdominal sonography of emergency cases
- To confidently perform femoral artery and venous puncture techniques
- To confidently perform image guided drainage of fluid collections under supervision
- To perform percutaneous transhepatic drainage of the biliary tract under supervision
- To perform in other interventional emergency procedures under image guidance, particularly in bleeding control under supervision
- To confidently identify modality dependent imaging findings of misplacement of devices such as ventilation, drainage or catheter tubes
- To confidently identify modality and body region dependent common imaging findings in emergency cases such as fracture patterns, ileus signs, free air and fluids, bleedings, infarctions, organ injury
- To confidently classify modality dependent imaging findings to be potentially acute life-threatening, in principal but not immediately life-threatening, severe but not life-threatening or other
- To confidently classify modality dependent imaging findings according to curricular content provided by corresponding other subspecialties
- To perform image interpretation or therapy of >1000 emergency cases (>300 CR, >50 eFAST, >100 US, >300 CT including >20 polytrauma cases and >20 Triple-rule-outs, >50 MRI, >10 embolisations, >10 PTD, >30 drainage of fluid collections). These cases have to distribute commonly over the body regions and the typical pathologies
- To interpret, report, communicate and demonstrate common and typical findings
- To interpret, report, communicate and demonstrate rare findings under supervision
- To supervise the imaging quality of emergency CT, radiographic and MRI examinations including image post-processing
- To manage procedural complications of imaging in the emergency setting

## COMPETENCES AND ATTITUDES

- To confidently differentiate high-risk from low-risk patients before imaging
- To confidently differentiate and prioritise findings with respect to their urgency after imaging
- To confidently 'screen' as fast as possible for life-threatening findings (e.g. for CT: <10 min after scan start) using an optimised infrastructure and selective image reading in case of high-risk patients
- To have an in-depth understanding of the respective advantages and disadvantages of different imaging options in emergency cases
- To be able to choose and to justify the probably best-suited particular imaging modality and protocol parameters and, if necessary, to properly put imaging techniques into a most appropriate diagnostic pathway considering advances and limitations of the different modalities, diagnostic accuracy and speed, amount of radiation exposure and ethically motivated corresponding individual risk/benefit-analysis with respect to case severity, time-to-diagnose/therapy, patient age and sex including pregnant patients
- To be integral and active part of continuous workflow optimisation with particular respect to ethical considerations, improvement of diagnostic accuracy and shortening of the time-to-diagnose/therapy
- To perform actively at multi-disciplinary therapy, morbidity and mortality conferences
- To perform in and be active part of QA, QM
- To supervise, teach and train technical staff to ensure with respect to appropriate emergency workflow and imaging
- To communicate timely and properly with patients (if possible), their relatives (if adequate) and the involved other medical disciplines in order to explain imaging findings, disorders and to rapidly evaluate adequate therapy with respect to best possible outcome.
- To participate in QA, QM
- To appreciate own limitations and to respect the roles and responsibilities of other members of the multidisciplinary emergency team, being an integral part of the team in decision-making.

## B-II-5

**GASTROINTESTINAL AND ABDOMINAL RADIOLOGY****KNOWLEDGE****IMAGING TECHNIQUES – GENERAL REQUIREMENTS**

- To describe the indications and contraindications for the various imaging examinations in abdominal imaging
- To describe the relative costs of the various imaging examinations in abdominal imaging
- To understand the radiation burden and risks of different investigations in abdominal imaging
- To describe the indications and contraindications for enema techniques and the optimal contrast material and technique to be used in each clinical situation
- To list the indications for a contrast-enhanced ultrasound study of the liver
- To describe the techniques for quantification of diseases using ultrasound, CT and MRI, and their clinical role and limitations in abdominal imaging
- To describe the anatomy of the retroperitoneal structures and the application and limitations of ultrasound in this area
- To list the strengths and limitations of endosonography in abdominal imaging
- To describe the techniques for CT colonography, CT/MR enterography and CT/MR enteroclysis
- To describe the techniques and role for post-processing images in view of obtaining reformatting, MIP, MinIP, vessel analysis, 3D analysis, including endoluminal reconstructions, fusion images, as well as acquisition and postprocessing of functional studies in abdominal imaging
- To describe the technique of PET-CT, the most important tracers (FDG, choline) and the development of new tracers, and sensitivity and specificity of PET-CT in most common abdominal tumours, including liver metastases of extra-abdominal origin
- To describe the imaging features of pneumoperitoneum, mechanical obstruction and pseudo-obstruction, toxic dilatation of the colon, gas in the small and large bowel wall that may indicate ischaemia and necrosis, pancreatic and biliary calcifications and aerobilia on plain abdominal films
- To understand the principles and limitations of single and double studies of the gastrointestinal tract and to appreciate their advantages and disadvantages compared with endoscopy
- To describe the anatomical components of the rectum and colon and normal findings with different imaging techniques
- To describe the main indications, contraindications and basic technique for ablation of liver tumours using ultrasound and/or CT guidance
- To describe the technique of trans-jugular liver biopsy
- To describe the basic principles of balloon angioplasty and stenting of abdominal visceral arteries for the treatment of stenosis and aneurysms
- To describe the rationale, technique, principle and results of therapeutic embolisation and transarterial chemoembolisation in the abdomen

## ANATOMY AND PHYSIOLOGY

- To understand the principal aspects of embryology of the oesophagus, stomach, duodenum, small bowel, appendix, colon, rectum, anus, pancreas, liver, biliary tract and spleen
- To understand the indication and techniques for interventional procedures within the abdomen, including hepatobiliary intervention and luminal stenting
- To have an in-depth knowledge of the anatomy of the pharynx, oesophagus, stomach, duodenum, small bowel, appendix, colon, rectum, anus, pancreas, liver, biliary tract, spleen, mesentery and peritoneum
- To have an in-depth knowledge of the anatomy of the pelvic floor and abdominal wall
- To describe arterial supply and venous drainage, including important variants, of the various portions of the gastrointestinal tract
- To describe the lymphatic drainage of the relevant organs in the abdomen
- To describe the main anatomical variants that may mimic disease in abdominal imaging
- To describe normal post-therapeutic imaging related to previous surgery, intervention or radiation therapy in the abdomen
- To describe the various phases of contrast media application (plain, arterial, portal, delayed, hepatobiliary) and their respective values according to the clinical problem in abdominal imaging

## OESOPHAGUS

- To describe the imaging features of oesophageal perforation on plain films, and to appreciate the relative role of contrast studies and CT for confirmation
- To describe the imaging features of oesophageal cancer, diverticulum, extrinsic compression, submucosal masses, fistulae, sliding and para-oesophageal hiatus hernia, oesophageal varices, benign strictures, benign tumours, varices, different forms of oesophagitis on a contrast-enhanced examination of the oesophagus
- To understand the significance of Barrett's oesophagus and the clinical manifestations of this disease
- To describe the appearance of common motility disorders of the oesophagus
- To understand the role of PET or PET-CT in the staging of oesophageal cancer
- To have a basic understanding of the surgical techniques in oesophageal surgery and post-surgical appearances on imaging examinations
- To describe the imaging features of oesophageal cancer on CT and to describe the criteria for non-resectability and lymph node involvement
- To understand the use of endoscopic ultrasound in the staging of oesophageal cancer and the technique of endoscopic ultrasound-guided biopsy

## STOMACH AND DUODENUM

- To describe the most appropriate imaging examination and contrast medium use in suspected perforation of the stomach and postoperative follow-up and to list the limitations of each examination for these specific conditions
- To understand the role of endoscopic ultrasound and PET or PET-CT in the staging of gastric cancer
- To describe a CT protocol tailored for gastric cancer staging
- To have a basic understanding of the surgical procedures for the treatment of obesity and the radiological postoperative appearance and complications
- To have a basic understanding of the imaging features of a variety of conditions of the stomach and duodenum such as benign and malignant tumours, infiltrative disorders, e.g. linitis plastica, gastric ulcers and positional abnormalities, including gastric volvulus
- To describe the imaging features of duplication cysts of the upper gastrointestinal tract on CT
- To describe rotational abnormalities of the duodenum and the appearance of annular pancreas, submucosal tumours, papillary tumours, and inflammatory disease including ulceration

## SMALL BOWEL

- To describe the most appropriate imaging examination for small bowel obstruction, inflammatory disease, infiltrative disease, small bowel perforation and ischaemia, cancer, lymphoma, carcinoid tumour and post-operative follow-up; and to list the limitations of each examination for these specific cases
- To describe the imaging features of lymphoid hyperplasia of the terminal ileum on small bowel series; and to describe the most common mid-gut abnormalities (malrotation, internal hernia)
- To describe the MRI and CT techniques of enterography and enteroclysis
- To describe the indications for capsule endoscopy and to list the limitations and potential complications of the examination
- To describe imaging features of small bowel abnormalities, including stenosis, fold abnormalities, nodules, tumours, ulcerations, wall thickening, marked angulation, extrinsic compression and fistula
- To describe the imaging features of the following disorders on a small bowel series: adenocarcinoma, polyposis, stromal tumour, lymphoma, carcinoid tumour, Crohn's disease, haematoma, Whipple's disease, amyloidosis, radiation-induced injury, malrotation, Meckel's diverticulum, coeliac disease, diverticulosis and systemic sclerosis
- To understand the principles of the interpretation of CT examination of the small bowel
- To describe the typical findings in the various diseases of the small bowel, including the halo sign and the target sign, the transitional zone in the case of small bowel obstruction, small bowel tumours, mural pneumatosis, vascular engorgement, increased density of the mesenteric fat, peritoneal abnormality and malrotation
- To describe the imaging features, causes and complications of small bowel obstruction on CT (adhesion, band, strangulation, intussusception, volvulus, internal and external hernias, tumours) and to list the criteria for emergency surgery
- To describe the interpretation of MRI of the small bowel, especially in cases of inflammatory bowel disease

## COLON AND RECTUM

- To understand the normal anatomy of the colon, rectum, perirectal tissues and of the anal sphincters
- To describe the optimal imaging examination and outline the technique for study of the colon according to the suspected disease (obstruction, volvulus, diverticulitis, benign tumour, inflammatory disease, cancer, lymphoma, uncommon lesions of the colon and rectum, perforation, postoperative evaluation) and to list the limitations of each technique
- To understand rotational abnormalities of the colon
- To have an in-depth understanding of the imaging appearance of the appendix on CT and ultrasound and of the imaging features of appendicitis and mucocele
- To understand the current indications for CT colonography, including its potential role in colorectal cancer screening
- To describe the TNM classification of colon cancer and its prognostic value, the technique and the value of MDCT, MRI and endosonography, in the staging of rectal cancer
- To describe the CT imaging features of colon cancer and signs that assess local extent (enlarged lymph nodes, peritoneal carcinomatosis, hepatic metastases)
- To describe the MRI technique for rectal cancer
- To describe the staging of the tumour according to the tumour proximity with the mesorectal fascia and distance to the sphincter and to describe the potential limitations of MRI for lymph node staging
- To describe imaging patterns and modalities used to assess for locally recurrent or metastatic colorectal cancer
- To describe the criteria that may help in differentiating between postoperative fibrosis and rectal tumour recurrence in the pelvis
- To describe the appearances and differential diagnosis of retrorectal cysts
- To describe the most common diseases of the rectum and the anus and the most frequent operative techniques that may be used to treat them
- To have a basic understanding of the MRI technique that is used to search for a pelvic/perianal fistula and to describe the appearance of fistulae on MRI
- To describe the appearances of anal sphincter tears and perianal sepsis
- To describe the basic imaging features of functional and anatomical disorders on both fluoroscopic and MR proctography and the appearance of pelvic floor muscle tears and atrophy using MRI

## PERITONEUM AND ABDOMINAL WALL

- To describe the normal features of the peritoneum on ultrasound, CT and MRI
- To describe the various findings that can be seen in cases of peritoneal disease (nodules, thickening, fluid collection)
- To describe the various types of abdominal wall hernias (inguinal, femoral, umbilical, Spigelian, parastomal, postoperative) on CT and on ultrasound
- To describe the imaging features of hernial strangulation on CT and on ultrasound
- To describe the imaging features of mesenteric tumour and its location on ultrasound, CT and MRI
- To describe the imaging features of mesenteric cysts on ultrasound, CT and MRI
- To describe the imaging features of rectus sheath hematoma on ultrasound, CT and MRI
- To describe the imaging features of ascites on ultrasound, CT and MRI and to describe the features of loculated ascites
- To describe the imaging features and basic clinical features of the following peritoneal diseases on CT and MRI: peritonitis, peritoneal carcinomatosis, peritoneal tuberculosis, mesenteric lymphoma, mesenteric and greater omental infarction

## ABDOMINAL VESSELS

- To understand the basic principles of Doppler ultrasound and superior mesenteric artery stenosis or occlusion
- To understand the use of Doppler ultrasound to assess the patency of and the direction of flow in the portal and hepatic veins
- To describe the respective roles of angiography and CT angiography in acute gastrointestinal haemorrhage
- To describe the angiographic and CT appearances of acute haemorrhage and to describe the advantages and limitations of the techniques
- To understand the imaging appearance of small bowel ischaemia/infarction on CT
- To describe the angiographic imaging features of occlusion, stenosis and aneurysms of the mesenteric arteries

## LIVER

- To have a detailed understanding of liver anatomy and segmentation and vessel anatomy (hepatic artery, portal vein, hepatic veins, inferior vena cava), including variants in vascular anatomy that may affect surgical planning
- To describe the most common surgical procedures for hepatectomy and liver transplantation
- To describe the imaging features and basic clinical features of vascular diseases of the liver, including Budd-Chiari Syndrome, Osler-Weber disease, portal thrombosis, peliosis and sinusoidal obstruction syndrome
- To describe the imaging features of a typical biliary cyst on ultrasound, CT and MRI
- To describe the imaging features of hydatid cysts on ultrasound, CT and MRI
- To differentiate between amoebic abscess and pyogenic abscess of the liver in regard to appearance, evolution, treatment, and indication for drainage
- To describe the imaging features of liver haemangiomas on ultrasound (including ultrasound contrast agents), CT and MRI



- To describe the imaging features of focal nodular hyperplasia and liver cell adenoma including subtypes on ultrasound, Doppler, contrast-enhanced ultrasound, CT and MRI, including hepato-biliary contrast agents
- To describe the imaging features of homogeneous and heterogeneous liver steatosis on ultrasound, CT and MRI (including imaging quantification)
- To describe the natural history of hepatocellular carcinoma (HCC), the major techniques and the indications for treatment (surgical resection, chemo- or radioembolisation, percutaneous ablation, liver transplantation, oral targeted therapy)
- To describe the imaging features of HCC on ultrasound (including Doppler), CT and MRI
- To describe the staging of HCC in order to discuss indications for treatment
- To describe the typical imaging features of liver metastases on ultrasound (including Doppler and ultrasound contrast agents), CT and MRI, including MRI with hepato-biliary contrast agents, and to describe the sensitivity and specificity of each
- To describe the imaging features of peripheral cholangiocarcinoma, and to describe the staging and consequences on treatment possibilities (surgery, palliation)
- To describe the most common morphological changes associated with liver cirrhosis, including lobar atrophy or hypertrophy, regeneration nodules, fibrosis
- To list the main causes of liver cirrhosis
- To describe the principles and methods for fibrosis quantification using ultrasound and MRI
- To describe rare tumours of the liver and their radiological appearance
- To describe the imaging appearance and quantification of liver iron overload
- To describe the technique for percutaneous image-guided liver biopsy and its most common indications
- To describe the complications of percutaneous image-guided liver biopsy and to precisely evaluate the occurrence of morbidity and mortality
- To describe the role of hepato-biliary contrast media
- To describe current application of diffusion-weighted imaging of the liver

## BILIARY TRACT

- To know the strengths and weaknesses of different imaging methods for the detection of gall bladder and common bile duct stones
- To describe the imaging features and clinical features of acute cholecystitis on ultrasound (including Doppler) and CT
- To describe unusual features of cholecystitis like gangrenous, emphysematous and acalculous cholecystitis on ultrasound and CT
- To list the main causes of gallbladder wall thickening on ultrasound
- To describe the imaging features of gallbladder cancer on ultrasound, CT and MRI
- To describe the imaging features of gallbladder adenomyomatosis on ultrasound, CT and MRI
- To describe the imaging features of cholangiocarcinoma of the liver hilum (Klatskin's tumour) and to describe the tumour staging, with regard to treatment options (resectability, indication for palliation)

- To describe the imaging features of an ampullary carcinoma on ultrasound, CT and MRI, including magnetic resonance cholangiopancreatography (MRCP) and endoscopic ultrasound
- To describe the typical imaging features of sclerosing cholangitis on ultrasound, CT and MRI, including MRCP; know the natural history and possibility of associated cholangiocarcinoma
- To describe the main techniques for surgery of the bile duct and its common complications
- To describe the imaging features of biliary leaks on imaging examinations

## PANCREAS

- To describe the natural history of chronic pancreatitis and to list the common causes
- To describe the imaging features of pancreatic calcifications on plain films, ultrasound and CT
- To list the indications and rationale for functional examinations of the pancreas (e.g. MRCP following secretin stimulation)
- To describe the value of clinico-biological (Ranson score, APACHE II) and CT (Balthazar's CT severity score) methods for the grading of acute pancreatitis
- To describe the typical imaging features of pancreatic and peri-pancreatic collections in the case of acute pancreatitis: acute peripancreatic fluid collection and pseudocyst for interstitial edematous pancreatitis, acute necrotic collection and walled-off necroses for necrotizing pancreatitis
- To describe the typical imaging features of pancreatic adenocarcinoma on ultrasound, CT, MRI and endoscopic ultrasound
- To describe the tumour staging for pancreatic adenocarcinoma including criteria for unresectability
- To describe the typical imaging features of cystic tumours of the pancreas, including serous and mucinous cystadenoma, intraductal mucinous tumours; the indications and modalities used for tumour characterisation and the indication for follow-up imaging for IPMN
- To describe the main techniques for pancreatic surgery and to list their potential complications
- To describe the imaging features of a pancreatic pseudocyst and to discuss the advantages and limitations of different treatments (follow-up, interventional procedure, percutaneous or endoscopic surgery)

## SPLEEN

- To describe optimal imaging strategies for the spleen according to the indication (e.g. trauma, staging of lymphoproliferative disorders, investigation of a focal lesion etc.)
- To list the causes and imaging features of focal splenic abnormalities, including infection and both benign and malignant masses
- To describe the causes of splenic calcification
- To list the causes of splenic enlargement

## SKILLS

- To choose the most appropriate imaging examination according to the clinical problem in abdominal imaging
- To choose the most suitable contrast material and its optimal use according to the imaging technique and the clinical problem in abdominal imaging
- To perform video-fluoroscopy of the swallowing mechanism
- To perform contrast studies of the upper gastrointestinal tract with the most appropriate contrast material
- To perform both single and double contrast studies as well as motility assessments of the gastrointestinal tract
- To perform small bowel follow-through and enteroclysis, including catheter placement beyond the ligament of Treitz
- To perform a motility assessment and a single contrast enema
- To catheterise a stoma for colon opacification and to perform pouchograms and loopograms
- To confidently plan a CT examination of the abdomen and to tailor it to the individual situation in regard to intravenous contrast medium, rate of injection, dose and delay of the contrast medium and to a potential intraluminal contrast medium application, with a dose as low as reasonably achievable
- To confidently plan an MRI examination of the upper abdomen and to tailor it to the individual situation in regard to the potential use of intravenous contrast medium, rate of injection, dose and delay of the contrast medium, potential intraluminal contrast medium, magnetic resonance cholangiopancreatography (MRCP)
- To confidently plan an MRI examinations of the small bowel, rectum and anal canal and to adapt it to the individual situation, including the application of endoluminal contrast
- To perform CT and MR examination for recognising the anatomical variants of the pancreatic duct (e.g. annular pancreas)
- To apply techniques for quantification of diseases using ultrasound, CT and MRI, based on an in-depth understanding of their clinical role and limitations.
- To perform MRI and CT enterography and enteroclysis
- To perform ultrasound examinations of the liver, gall bladder, biliary tree, pancreas and spleen
- To perform duplex Doppler examinations of the abdominal vessels; recognising the normal findings of the duplex Doppler study of the hepatic artery, superior mesenteric artery, portal vein and hepatic veins
- To perform ultrasound examinations of the gastrointestinal tract and to identify the various portions (stomach, duodenum, small bowel, appendix and colon)
- To perform ultrasound examinations of the abdomen in patients with suspected inflammatory bowel disease
- To perform contrast-enhanced ultrasound examinations of the liver under supervision

- To perform CT colonography
- To perform basic and advanced post-processing tasks for abdominal imaging studies, including maximum intensity projections (MIP), minimum intensity projections (MinIP), volume rendering, vessel analysis tools, endoluminal reconstructions, and fusion images in abdominal imaging

**Competency or experience in all of the following interventional procedures is unlikely to be achieved by many radiologists.**

**However, practical experience in at least 3 of the following examinations is expected:**

- To perform percutaneous image-guided liver biopsy under supervision
- To perform biopsy of abdominal tumours with an easy access route under ultrasound or CT guidance
- To drain abdominal abscesses with an easy access route under ultrasound or CT guidance
- To assist and/or perform under supervision image-guided interventions in colon cancer, e.g. colonic stent placement in the case of colonic obstruction
- To assist and/or perform under supervision percutaneous gastrostomy under image guidance
- To assist and/or perform under supervision percutaneous cholecystostomy under supervision
- To assist and/or perform under supervision percutaneous biliary interventions
- To assist and/or perform under supervision radiologically guided stenting of the biliary system and gastrointestinal system, using polytetrafluoroethylene and expandable metal stents
- To assist and/or perform under supervision the ablation of liver tumours using ultrasound and/or CT guidance
- To assist and/or perform under supervision trans-jugular liver biopsies
- To assist and/or perform under supervision balloon angioplasty and stenting of the mesenteric arteries for the treatment of stenosis and aneurysms
- To perform under supervision transarterial chemoembolisation and simple embolization for acute abdominal bleeding control
- To assist radio-embolisation procedures

## COMPETENCES AND ATTITUDES

- To confidently justify diagnostic imaging examinations and/or interventional procedures of the abdomen and/or gastrointestinal system
- To confidently choose the best method for evaluating disorders of the abdomen and/or gastrointestinal system
- To communicate with the patient in order to obtain informed consent prior to diagnostic imaging and interventional procedures of the abdomen and/or gastrointestinal system
- To confidently choose optimal imaging parameters for radiographic, ultrasonographic, CT and MRI examinations of the abdomen and/or gastrointestinal system
- To confidently apply techniques to reduce exposure doses for radiographic and CT examinations of the abdomen
- To confidently design imaging protocols and standard operating procedures for CT examinations of the abdomen and gastrointestinal system, including the appropriate application of intravenous and/or intraluminal contrast, spatial and temporal resolution, and inspiration/expiration/breathhold techniques
- To confidently design imaging protocols and standard operating procedures for MRI examinations of the upper abdomen and gastrointestinal system, including the appropriate application of intravenous and or intraluminal contrast, spatial and temporal resolution, and inspiration/expiration/breathhold techniques
- To supervise and teach technical staff to ensure that appropriate images are obtained in abdominal imaging
- To confidently judge the quality of the imaging examinations in abdominal imaging and to devise strategies to improve image quality
- To confidently report abdominal radiographs in cases of acute abdomen
- To confidently interpret and report abdominal radiographs, ultrasonographic examinations, abdominal CT studies and MRI examinations of the upper abdomen, small bowel, rectum and anal canal
- To report oncological studies of the abdomen according to international standards (RECIST, WHO) applicable to the specific situation
- To appreciate own limitations and to identify when it is appropriate to obtain assistance in interpreting and reporting images of the abdomen and gastrointestinal system
- To confidently identify urgent and/or unexpected findings in imaging examinations of the abdomen and gastrointestinal system and to communicate these timely and properly
- To communicate under supervision with patients and their relatives in order to explain their imaging findings of the abdomen and gastrointestinal system
- To perform under supervision multi-disciplinary conferences and tumour boards for diseases of the abdomen and gastrointestinal system

## B-II-6 GYNAECOLOGICAL AND OBSTETRIC RADIOLOGY

### KNOWLEDGE

#### ANATOMY

- To have a detailed understanding of the normal anatomy of the female reproductive organs
- To have a detailed understanding of the physiological changes affecting normal imaging anatomy of the female reproductive organs throughout the lifespan
- To have a detailed understanding of the physiological changes of the female reproductive organs during pregnancy
- To describe the dimensions of the uterus and ovaries with ultrasound
- To understand the variations of the uterus and ovaries during genital life
- To understand the variations of the uterus and ovaries during the menstrual cycle
- To list the normal pelvic compartments
- To describe the normal pelvic organs and boundaries on CT and MRI
- To describe the role of the levator ani in the physiology of the pelvic floor

#### CONGENITAL

- To list congenital malformations of the uterus, including uterus septatus, uterus bicornis (unicollis and bicollis) and uterus didelphys
- To describe the typical imaging features of congenital malformations of the uterus, including uterus septatus, uterus bicornis (unicollis and bicollis) and uterus didelphys

#### UTERUS

- To describe the indications and contraindications of transvaginal sonography and hysterosonography
- To describe the imaging features and basic clinical features of benign tumours of the myometrium
- To describe the imaging features and basic clinical features of malignant tumours of the myometrium
- To describe the imaging features and basic clinical features of tumours of the endometrium
- To describe the imaging features and basic clinical features of adenomyosis uteri
- To describe the imaging features and basic clinical features of cervical inflammation
- To describe the imaging features and basic clinical features of cervical cancer
- To describe the imaging features and basic clinical features of functional disorders of the cervix
- To describe the imaging features and basic clinical features of endometriosis
- To describe the imaging features and clinical features of uterine leiomyomas of different sizes

- To describe the image-guided therapeutic approaches to uterine leiomyomas
- To describe typical imaging features of the uterus after different types of gynaecological surgeries
- To describe typical imaging features of the uterus after different types of image-guided therapies

## PREGNANCY

- To describe the imaging features and basic clinical features of uterine disorders associated with pregnancy
- To describe the imaging features and basic clinical features of uterine disorders during delivery
- To describe the imaging features and basic clinical features of uterine disorders in the post-partum period
- To describe the image-guided therapeutic approaches in severe post-partum bleeding
- To describe imaging strategies in pregnant patients with symptoms of an acute abdomen
- To describe typical imaging and clinical features in pregnant patients with symptoms of an acute abdomen
- To describe the principles of MR pelvimetry
- To list the relevant parameters of MR pelvimetric measurements
- To describe the principles of fetal MR imaging technology
- To have a basic understanding of the various stages of embryonic and fetal development and their respective appearance on MR imaging

## OVARIES / ADNEXE / INFERTILITY

- To describe the procedure, possible complications, choice of contrast agent, indications and contraindications of hysterosalpingography
- To describe the different phases of hysterosalpingography
- To describe the imaging features and basic clinical features of ovarian cysts
- To describe the imaging features and basic clinical features of benign ovarian tumours
- To describe the imaging features and basic clinical features of malignant ovarian tumours
- To describe the imaging features and basic clinical features of functional disorders of the ovaries
- To describe the imaging features and basic clinical features of inflammatory disorders of the tubes
- To describe the imaging features and basic clinical features of tumours of the tubes
- To describe the imaging work-up and features of infertility
- To describe the imaging features and basic clinical features of ovarian torsion
- To describe the imaging features and basic clinical features of changes and disorders of the ovaries associated with pregnancy and the post-partum period
- To describe typical imaging features of the ovaries after different types of gynaecological surgeries
- To describe typical imaging features of the ovaries after different types of image-guided therapies

## PELVIC FLOOR

- To list imaging techniques that can be used to visualise the female pelvic floor
- To describe the imaging features and basic clinical features of descensus uteri and pelvic prolapsed
- To describe factors responsible for female urinary incontinence

## SKILLS

- To choose the most appropriate imaging examination according to the clinical problem in gynaecological and obstetric radiology
- To choose the most suitable contrast material and its optimal use according to the imaging technique, the clinical problem and the age in gynaecological and obstetric radiology
- To confidently perform a transabdominal and/or transvaginal ultrasound in gynaecological disorders
- To confidently perform a transabdominal and/or transvaginal ultrasound in pregnant patients
- To perform hysterosalpingography
- To confidently plan a CT examination in gynaecological and obstetric radiology and to tailor it to the individual situation with a dose as low as reasonably achievable
- To confidently plan an MRI examination in gynaecological and obstetric radiology and to tailor it to the individual situation of the patient in regard to the potential use of intravenous contrast medium and spatial resolution
- To perform a pelvimetric MR examination in the pregnant patient
- To observe and/or perform under supervision image-guided biopsies, e.g. of kidney masses
- To observe and/or perform under supervision image-guided drainage procedures in the urogenital tract
- To observe and/or perform under supervision percutaneous nephrostomy
- To confidently perform proper post-processing tasks of examinations in paediatric urogenital radiology, including multi-planar reformations (MPR), maximum intensity projections (MIP), minimum intensity projections (MinIP), and fusion images



## COMPETENCES AND ATTITUDES

- To justify diagnostic imaging examinations and/or interventional procedures of the female reproductive organs
- To choose the best-suited method for evaluating disorders of the female reproductive organs
- To communicate with the patient in order to obtain informed consent prior to diagnostic imaging and interventional procedures of the female reproductive organs
- To choose optimal imaging parameters for radiographic, ultrasonographic, CT and MRI examinations of the female reproductive organs
- To apply techniques to reduce exposure doses for radiographic and CT examinations of the female reproductive organs
- To choose the optimally suited imaging modality for pregnant patients
- To design imaging protocols for CT examinations of the female reproductive organs and for staging in patients with tumours of the female reproductive organs
- To design imaging protocols for MRI examinations of the female reproductive organs including the appropriate application of intravenous and/or intraluminal contrast and spatial and temporal resolution
- To supervise and teach technical staff to ensure that appropriate images of the female reproductive organs are obtained
- To interpret and report radiographs, CT and MRI examinations of patients with disorders of the female reproductive system
- To report oncological studies in patients with tumours of the female reproductive system according to international standards (FIGO, RECIST, WHO) applicable to the specific situation
- To appreciate own limitations and to identify when it is appropriate to obtain assistance in interpreting and reporting images of the female reproductive system
- To confidently identify urgent and/or unexpected findings in imaging examinations of the female reproductive system and to communicate these timely and properly
- To emphatically communicate with patients and their relatives in order to explain imaging findings in disorders of the female reproductive system
- To perform at multi-disciplinary conferences and tumour boards for diseases of the female reproductive system

## B-II-7 HEAD AND NECK RADIOLOGY

### KNOWLEDGE

#### NORMAL ANATOMY

- To have a good knowledge of the temporal bone, facial skeleton, skull base, cranial nerves, orbits and visual pathways, sinuses, pharynx, oral cavity, mandible, teeth, temporomandibular joints, salivary glands, larynx, neck, deep spaces of the face and neck, thoracic inlet and brachial plexus, as well as the thyroid gland and parathyroid glands
- To describe normal variants of the temporal bone, facial skeleton, skull base, cranial nerves, orbits and visual pathways, sinuses, pharynx, oral cavity, mandible, teeth, temporomandibular joints, salivary glands, larynx, neck, deep spaces of the face and neck, thoracic inlet and brachial plexus, as well as the thyroid gland and parathyroid glands and to differentiate these from disease
- To describe the terminology for describing the site of lymph nodes in the head and neck region

#### TEMPORAL BONE

- To list and to describe the imaging features of congenital disorders leading to deafness (e.g. cochlear aplasia/hypoplasia, Mondini malformation, large endolymphatic sac anomaly (LESA) / large vestibular aqueduct syndrome (LVAAS))
- To list disorders leading to secondary deafness including otosclerosis, Menière's disease, and temporal bone inflammatory disease
- To describe the imaging features and basic clinical features of disorders leading to secondary deafness including otosclerosis, Menière's disease, temporal bone inflammatory disease, and tumours of the cerebellopontine angle
- To confidently delineate the course of the facial nerve in its different components
- To describe the imaging features and basic clinical features of tumours of the temporal bone and to distinguish these from each other
- To describe the imaging features and basic clinical features of tumours of the cerebellopontine angle and to distinguish these from each other
- To describe the imaging features and basic clinical features of traumatic lesions and fractures of the temporal bone
- To describe the imaging features and basic clinical features of cholesteatoma
- To differentiate different pathologies of the external auditory canal, including atresia and tumorous lesions
- To differentiate different pathologies of the middle ear
- To be familiar with the different types of cochlea implants and their respective MRI compatibility / non-compatibility (including specific precautions)
- To list the various causes of vascular tinnitus and to describe their respective imaging features

## FACIAL SKELETON, SKULL BASE AND CRANIAL NERVES

- To list the different neoplasms of the clivus and to describe their respective imaging appearance, including meningioma, macroadenoma and clivus chordoma
- To describe the imaging features and basic clinical features of lesions of the jugular foramen, including glomus tumour / paraganglioma, jugular bulb pseudolesion, jugular bulb diverticulum, dehiscent jugular bulb, jugular foramen schwannoma, and jugular foramen meningioma
- To describe the imaging features and basic clinical features of diffuse diseases of the skull base, including fibrous dysplasia, plasmocytoma, Langerhans cell histiocytosis, chondrosarcoma and metastases
- To describe the normal anatomy and function of the cranial nerves and to list common pathologies
- To list and categorize traumatic lesions of the facial skeleton and to be familiar with complications and therapeutic consequences
- To describe the typical imaging features of neoplasms of the mandible and maxilla
- To understand the imaging features of dentigerous cysts and odontogenic keratocysts
- To understand the imaging features of infectious and inflammatory lesions of the mandible, maxilla and skull base, including osteomyelitis

## ORBIT AND VISUAL PATHWAYS

- To describe the imaging features and basic clinical features of congenital lesions of the orbit, including coloboma
- To describe the imaging features and basic clinical features of typical tumours of the orbit in children including dermoid and epidermoid cysts, cavernous haemangioma, lymphangioma, rhabdomyosarcoma and retinoblastoma
- To describe the orbital manifestations of neurofibromatosis type I
- To describe the imaging features and basic clinical features of infectious and inflammatory disorders of the orbits including optic neuritis, abscesses, sarcoidosis and idiopathic inflammatory disorders
- To describe the imaging features and basic clinical features of benign tumours of the orbits including meningioma, optic/chiasmal glioma, orbital haemangioma, and benign mixed tumour of the lacrimal gland
- To describe the imaging features and basic clinical features of malignant tumours of the orbits including ocular melanoma, orbital lymphoma, higher grade optic / chiasmal glioma, adenoid cystic carcinoma of the lacrimal glands

## NOSE, NASOPHARYNX AND PARANASAL SINUSES

- To describe the imaging features and basic clinical features of congenital lesions of the paranasal sinuses including choanal atresia and frontoethmoidal encephalocele
- To differentiate normal variants of the nose and paranasal sinuses from pathology
- To describe the imaging features and basic clinical features of infectious and inflammatory disorders of the nose and paranasal sinuses including acute and chronic rhinosinusitis, fungal sinusitis, sinonasal polyposis, sinonasal mucocele and sinonasal Wegener granulomatosis

- To be aware of typical complications of infectious and inflammatory disorders of the nose and paranasal sinuses
- To list and describe the typical surgical approaches to the nose and paranasal sinuses including functional endoscopic sinus surgery (FESS)
- To describe the imaging features and basic clinical features of benign and malignant neoplasms of the nose and paranasal sinuses including inverted papilloma, juvenile angiofibroma, sinonasal hemangioma, sinonasal osteoma, sinonasal fibrous dysplasia, sinonasal squamous cell carcinoma, sinonasal adenocarcinoma, sinonasal melanoma, esthesioneuroblastoma, and sinonasal lymphoma
- To describe the typical imaging features of the nose and paranasal sinuses after surgery
- To describe the imaging features and basic clinical features of the nasopharyngeal pathologies including Thornwaldt cyst, inflammatory and infectious lesions and neoplasms

## MASTICATOR SPACE, PAROTID SPACE AND CAROTID SPACE

- To describe the anatomical delineations of the masticator space, parotid space and carotid space
- To describe pseudolesions of the masticator space, including denervation atrophy, benign muscle hypertrophy and asymmetries of the pterygoid venous plexus
- To describe the typical imaging features of abscess formations of the masticator space
- To describe the imaging features and basic clinical features of benign and malignant neoplasms of the masticator space including peripheral nerve sheath tumours of the trigeminal nerve
- To describe the imaging features and basic clinical features of infectious and inflammatory lesions of the parotid space including parotitis, Sjogren syndrome and benign lymphoepithelial lesions in patients with HIV
- To describe the imaging features and basic clinical features of benign and malignant neoplasms of the parotid space including Warthin tumour, benign mixed tumour, adenoid cystic carcinoma, mucoepidermoid carcinoma, lymphoma, lymph node metastases and malignant tumors of the skin
- To describe the imaging features and basic clinical features of vascular lesions of the carotid space including ectatic carotid arteries, carotid artery pseudoaneurysm, carotid artery dissection, and jugular venous thrombosis
- To describe the imaging features and basic clinical features of neoplasms of the carotid space including carotid body paraganglioma, glomus vagale paraganglioma, schwannoma, and neurofibroma

## LYMPH NODES OF THE HEAD AND NECK REGION

- To have an in-depth understanding of the nomenclature of the lymph nodes and nodal regions
- To describe the imaging features and basic clinical features of infectious and inflammatory disorders of the lymph nodes including reactive lymph node enlargement, suppurative lymph nodes, Kimura disease, and Castleman disease
- To describe the imaging features and basic clinical features of neoplastic disorders of the lymph nodes, including lymphoma (Hodgkin and Non-Hodgkin) and nodal metastases
- To be familiar with PET-CT imaging findings in benign and malignant lymph nodes

## ORAL CAVITY, OROPHARYNX AND RETROPHARYNGEAL SPACE

- To describe the imaging features and basic clinical features of congenital lesions of the oral cavity and oropharynx, including dermoid and epidermoid cysts, accessory salivary tissue, lymphangioma and lingual thyroid gland
- To describe the imaging features and basic clinical features of inflammatory and infectious lesions of the oral cavity and oropharynx, including abscesses, retention cysts, sialoceles, sialadenitis and ranula
- To describe the imaging features and basic clinical features of benign and malignant neoplasms of the oral cavity and oropharynx, including benign mixed tumours, squamous cell carcinoma, malignant tumours of the minor salivary glands
- To describe the typical imaging features and clinical presentation of retropharyngeal abscesses

## HYPOPHARYNX AND LARYNX

- To describe the imaging features and basic clinical features of neoplasms of the hypopharynx and larynx, including squamous cell carcinoma of the hypopharynx, squamous cell carcinomas of the supraglottic, glottic and subglottic regions, and chondrosarcoma of the larynx
- To describe the typical imaging features of the hypopharynx and larynx after surgery and after radiation
- To describe the imaging features of vocal cord paralysis
- To describe the potential effects and the respective imaging features of laryngeal trauma
- To list the imaging features, causes and clinical consequences of tracheal stenoses
- To describe the imaging features of laryngoceles and pharyngoceles
- To describe functional abnormalities of the larynx and hypopharynx during impaired swallowing including primary and secondary aspiration and dysfunction of the crico-pharyngeal muscle
- To be familiar with PET-CT findings in head and neck tumours involving the pharynx, larynx and oral cavity

## THYROID AND PARATHYROID GLANDS AND VISCERAL LESIONS

- To describe the imaging features and basic clinical features of thyroiditis
- To describe the imaging features and basic clinical features of multinodular goiter
- To describe the imaging features and basic clinical features of benign and malignant neoplasms of the thyroid and parathyroid glands, including thyroid and parathyroid adenomas, different types of thyroid carcinoma, and thyroid lymphoma
- To describe the imaging features and basic clinical features of cervical oesophageal carcinoma
- To describe the imaging features and basic clinical features of a Zenker diverticulum and the typical approaches to therapy
- To be familiar with the most important findings of Tc-99m-scintigraphy in various diseases of the thyroid gland

## CONGENITAL AND TRANSSPATIAL LESIONS

- To have a basic understanding of the embryology of the head and neck region
- To describe the imaging features and basic clinical features of branchial cleft cysts
- To describe the imaging features and basic clinical features of thyroglossal duct cysts
- To describe the imaging features and basic clinical features of thymus cysts
- To describe the imaging features and basic clinical features of vascular lesions including malformations of the head and neck region
- To be familiar with the imaging manifestations of neurocutaneous syndromes, including neurofibromatosis type I, in the head and neck region
- To describe the imaging features and basic clinical features of fibromatosis colli

## SKILLS

- To choose the most appropriate imaging examination according to the clinical problem in head and neck imaging
- To choose the most suitable contrast material and its optimal use according to the imaging technique and the clinical problem in head and neck imaging
- To perform dynamic functional studies including video-fluoroscopy of the swallowing mechanism
- To ascertain correct positioning for imaging studies of the skull, sinus, skull base, and facial bones including special views
- To perform ultrasound including Doppler sonography of the neck, tongue, thyroid and salivary glands
- To perform percutaneous biopsy, guided by ultrasound or CT in straightforward/technically easy cases
- To perform fine needle aspiration biopsy in easy cases
- To perform lymph node aspiration biopsies in easy cases
- To observe and/or perform under supervision percutaneous biopsy, guided by ultrasound, CT and/or MRI in more complex cases
- To observe and/or perform under supervision dacryocystography
- To observe and/or perform under supervision fine needle aspiration biopsy in more complex cases
- To observe and/or perform under supervision lymph node aspiration biopsies in more complex cases
- To perform dental radiology
- To confidently plan a CT examination of the head and neck region and to tailor it to the individual situation in regard to intravenous contrast medium, rate of injection, dose and delay of the contrast medium, with a dose as low as reasonably achievable
- To confidently plan a CT examination of the temporal bone and to tailor it to the individual situation in regard to the potential use of intravenous contrast medium and spatial resolution
- To confidently plan an MRI examination of the head and neck region and to tailor it to the individual situation in regard to the potential use of intravenous contrast medium, rate of injection, dose and delay of the contrast medium, and spatial resolution
- To confidently plan an MRI examination of the temporal bone and to tailor it to the individual situation in regard to the potential use of intravenous contrast medium and spatial resolution

- To apply techniques for quantification of head and neck disorders using ultrasound, CT and MRI, based on an in-depth understanding of their clinical role and limitations
- To confidently perform proper post-processing tasks for head and neck imaging studies, including multi-planar reformations (MPR), maximum intensity projections (MIP), minimum intensity projections (MinIP), vessel analysis tools, endoluminal reconstructions, 3D reconstructions including volume rendering and virtual endoscopy and multimodality fusion of images

## COMPETENCES AND ATTITUDES

- To confidently justify diagnostic imaging examinations and/or interventional procedures of the head and neck region
- To confidently choose the best-suited method for evaluating disorders of the head and neck region
- To communicate with the patient in order to obtain informed consent prior to diagnostic imaging and interventional procedures of the head and neck region
- To confidently choose optimal imaging parameters for radiographic, ultrasonographic, CT and MRI examinations of the head and neck region
- To confidently apply techniques to reduce exposure doses for radiographic and CT examinations of the head and neck region
- To confidently design imaging protocols and standard operating procedures for CT examinations of the head and neck region, including the appropriate application of intravenous contrast, spatial and temporal resolution
- To confidently design imaging protocols and standard operating procedures for MRI examinations of the head and neck region, including the appropriate application of intravenous contrast, spatial and temporal resolution
- To supervise and teach technical staff to ensure that appropriate images of the head and neck region are obtained
- To confidently judge the quality of the imaging examinations in head and neck imaging and to devise strategies to improve image quality
- To confidently interpret and report radiographs, ultrasonographic examinations, CT studies and MRI examinations of the head and neck region
- To report oncological studies of the head and neck region according to international standards (e.g. TNM) applicable to the specific situation
- To appreciate own limitations and to identify when it is appropriate to obtain assistance in interpreting and reporting images of the head and neck region
- To confidently identify urgent and/or unexpected findings in imaging examinations of the head and neck region and to communicate these timely and properly
- To communicate with patients and their relatives in order to explain the imaging findings of the head and neck region
- To take an active part and/or conduct multi-disciplinary conferences and tumour boards for diseases of the head and neck region

## B-II-8 INTERVENTIONAL RADIOLOGY

### KNOWLEDGE

#### NON-INVASIVE VASCULAR IMAGING

- To describe the vascular anatomy on Duplex ultrasound, including both arterial and venous examinations
- To describe the characteristics of normal and abnormal Doppler waveforms
- To describe the typical imaging features on Doppler sonography of atherosclerotic disease, vasculitis, aneurismal disease, thrombosis, embolism and other vascular pathological conditions
- To describe the relevant acquisition parameters of CTA, including contrast materials used and reconstruction techniques
- To be aware of the radiation doses for CTA and to describe methods of reducing these
- To discuss advantages and disadvantages of CTA versus other techniques
- To describe the imaging features on CTA of atherosclerotic disease, vasculitis, aneurismal disease, thrombosis, embolism and other vascular pathological conditions
- To understand the physical principles of MR angiography (MRA) techniques
- To discuss the advantages and disadvantages of different contrast materials used for MRA
- To discuss the differences between time-of-flight, phase contrast, and contrast-enhanced techniques pertaining to MRA
- To discuss the advantages and disadvantages of MRA compared with other techniques
- To have an in-depth understanding of nephrogenic systemic fibrosis (NSF)
- To describe the typical imaging features on MRA of atherosclerotic disease, vasculitis, aneurismal disease, thrombosis, embolism and other vascular pathological conditions

#### DIAGNOSTIC ANGIOGRAPHY/VENOGRAPHY

- To describe the basic chemistry of the different iodinated contrast materials used, and to discuss the advantages/disadvantages of each for angiography
- To describe mechanisms to minimise nephrotoxicity in at-risk patients, such as patients with diabetes or renal impairment
- To describe the standard groin anatomy, including the position of the inguinal ligament and the femoral nerve, artery and vein
- To describe the Seldinger technique of arterial and venous puncture
- To describe the mechanisms for guidewire, sheath and catheter insertions into the groin
- To describe the mechanisms of puncture site haemostasis, including manual compression and common closure devices
- To describe alternative sites of arterial puncture, such as brachial, axillary and translumbar



- To list guidewires, sheaths and catheters used for common diagnostic angiographic procedures
- To describe digital subtraction angiography techniques, bolus chase techniques, road mapping and pixel shift techniques
- To have an in-depth understanding of the standard arterial and venous anatomy and variations in anatomy throughout the body
- To describe the principles of peripheral vascular angiography
- To describe the principles of mesenteric, coeliac and renal angiography
- To describe the principles of abdominal aortography
- To describe the principles of thoracic aortography
- To describe the principles of carotid, vertebral and subclavian angiography
- To describe the principles of venous venography
- To describe the imaging features on diagnostic angiography of atherosclerotic disease, vasculitis, aneurismal disease, thrombosis, embolism and other vascular pathological conditions
- To describe the complication rates for common diagnostic procedures
- To have an in-depth understanding of post-procedural care regimens for standard diagnostic vascular procedures
- To describe the principles of corticosteroid prophylaxis
- To describe the principles of treating both minor and major allergic reactions to iodinated contrast materials

## VASCULAR INTERVENTION

- To list the medical risk factors for atherosclerotic diseases
- To describe the clinical symptoms of peripheral arterial disease
- To list the indications for endovascular treatment of atherosclerotic diseases
- To describe the pre-procedure coagulation tests and the correction of abnormalities
- To describe the angioplasty balloon dynamics and the mechanism of action of angioplasty
- To describe the complications and results in different anatomical areas
- To list the drugs and dosages used during angioplasty
- To describe the principles of intra-arterial pressure studies
- To describe common angioplasty procedures, such as renal, iliac and femoral angioplasties
- To describe groin closure techniques and post-procedural care
- To describe potential groin complications and how to deal with them
- To describe the post-procedural care and medical treatment
- To describe typical complications and results of arterial stenting
- To describe the basic mechanisms for stent deployment and to list the materials used for stent construction
- To list the indications for stent placement versus angioplasty
- To describe post-procedural care after arterial stenting
- To describe peripherally inserted central catheter (PICC) lines, Hickman catheters, dialysis catheters and ports
- To list the indications for use of the above venous access catheters
- To describe the technique of access to jugular and subclavian veins

- To describe the technique of haemodialysis shunt interventions
- To describe the techniques of venoplasty and stenting
- To list the success rates and complications of venoplasty and stenting
- To describe the post-procedural care after venoplasty and stenting
- To list the indications for caval filter placement
- To describe the different filter types available, including retrievable filters
- To list the success rates and complications for caval filter placement
- To describe the post-procedural care for caval filter placement
- To describe the indications for embolisation such as acute bleeding, tumour therapy, AVM treatment
- To describe the technique of selective angiography
- To list embolisation materials and their specific use
- To describe the relevant catheters and microcatheters used for embolisation
- To list the endpoints of embolisation
- To discuss the risks of embolisation and specific embolisation materials
- To describe the treatment of post-embolic pain and post-embolic syndrome
- To be familiar with indications for transjugular intrahepatic portosystemic shunt (TIPS), the technique and complications

## BIOPSY AND THERMAL ABLATION

- To describe pre-procedure coagulation tests and the correction of abnormalities
- To describe differences in imaging techniques used for guiding biopsy, including CT and ultrasound
- To list needles used for biopsy procedures, including fine gauge needles, large gauge needles and trucut biopsy
- To describe safe access routes to various lesion to be biopsied
- To discuss complication rates associated with individual organ biopsy
- To list the indications for fine needle biopsy versus large gauge or core biopsy
- To describe the post-procedural care for chest and abdominal biopsy
- To list the algorithms for treatment of common complications, such as pneumothorax and haemorrhage
- To have an understanding of thermal ablation techniques in various organ systems

## FLUID ASPIRATION AND ABSCESS DRAINAGE

- To list commonly used chest tubes and abscess drainage catheters
- To describe the indications for chest drainage, fluid aspiration and abscess drainage
- To describe the imaging techniques used for guidance for fluid aspiration and abscess drainage
- To interpret Gram stain results
- To describe the methods of chest tube placement
- To describe underwater seal drainage systems

- To list fibrinolytic agents used in patients with loculated or complex empyemas
- To describe safe access routes for abscess drainage
- To list antibiotic regimens used before abscess drainage
- To describe the trocar and Seldinger techniques for catheter placement
- To list situations where more than one catheter is required
- To describe various approaches to pelvic abscess drainage
- To describe post-procedural care including catheter care, ward rounds and when to remove catheters

## HEPATOBIILIARY INTERVENTION

- To describe biliary anatomy that may influence biliary drainage
- To describe the pre-procedure work-up, including antibiotic regimens, coagulation screening and intravenous fluid replacement
- To describe the integration of ultrasound, CT and MRCP to plan an appropriate drainage procedure
- To describe the performance of transhepatocholangiography
- To describe one-stick needle systems and needle and guidewire for biliary drainage
- To list catheters used for biliary decompression
- To list complications of biliary procedures
- To describe the aftercare of hepatobiliary interventions, including knowledge of complications, catheter care and ward rounds

## GENITOURINARY INTERVENTION

- To describe the renal and calyceal anatomy that may influence nephrostomy drainage
- To list the indications for percutaneous nephrostomy
- To describe the integration of ultrasound, CT and urographic studies to plan an appropriate nephrostomy
- To describe the pre-procedural work-up including coagulation screens and antibiotic regimens
- To describe the ultrasound/fluoroscopic guidance mechanisms for percutaneous nephrostomy
- To list the catheters used for percutaneous nephrostomy
- To describe the placement of percutaneous nephrostomy tubes
- To describe the complications of percutaneous nephrostomy
- To describe the aftercare, including catheter care and removal

## SKILLS

- To confidently justify indications and to have an in-depth knowledge of the contraindications for common interventional radiology procedures
- To confidently treat both minor and major allergic reactions to iodinated contrast materials
- To perform radiation safety procedures in the interventional radiology suite
- To perform corticosteroid prophylaxis
- To perform groin closure techniques
- To treat potential groin complications
- To perform a correct pre- and post-procedural care and medical treatment
- To perform duplex ultrasound, including both arterial and venous examinations
- To perform common Doppler examinations, including carotid Doppler, hepatic and renal Doppler studies and lower extremity venous duplex examinations
- To perform the Seldinger technique of arterial and venous puncture
- To perform guidewire, sheath and catheter insertions into the groin
- To perform puncture site haemostasis, including manual compression and common closure devices
- To perform arterial puncture at alternative sites, such as brachial, axillary and translumbar sites
- To use guidewires, sheaths and catheters for common diagnostic angiographic procedures
- To perform digital subtraction angiography techniques, bolus chase techniques, road mapping and pixel shift techniques
- To perform peripheral vascular angiography
- To perform mesenteric, coeliac and renal angiography
- To perform abdominal aortography
- To perform thoracic aortography
- To perform under supervision carotid, vertebral and subclavian angiography
- To perform venography
- To perform post-procedural care regimens for standard diagnostic vascular procedures
- To perform pre-procedure coagulation tests and to correct abnormalities
- To perform common angioplasty procedures, such as renal, iliac and femoral angioplasties under supervision
- To choose the correct drugs and dosages during angioplasty
- To perform intra-arterial pressure studies
- To perform arterial stenting under supervision
- To perform post-procedural care after arterial stenting
- To observe and/or perform under supervision the placement of peripherally inserted central catheter (PICC) lines, Hickman catheters, dialysis catheters and ports
- To observe and/or perform under supervision haemodialysis shunt interventions
- To observe and/or perform under supervision venoplasty and stenting
- To observe and/or perform under supervision caval filter placement
- To observe and/or perform under supervision embolisation for indications such as acute bleeding, tumour therapy, AVM treatment

- To perform selective angiography
- To effectively treat post-embolic pain and post-embolic syndrome
- To observe and/or perform under supervision transjugular intrahepatic portosystemic shunt (TIPS)
- To perform transcutaneous, image-guided biopsy procedures, including fine gauge needle biopsies, large gauge needle biopsies and trucut biopsy
- To plan safe access routes to various lesions to be biopsied
- To treat common complications of biopsy, such as pneumothorax and haemorrhage
- To perform chest drainage, fluid aspiration and abscess drainage
- To use underwater seal drainage systems
- To apply fibrinolytic agents in patients with loculated or complex empyemas
- To choose safe access routes for abscess drainage
- To administer antibiotic regimens before abscess drainage
- To perform the trocar and Seldinger techniques for catheter placement
- To perform pelvic abscess drainage
- To perform transhepatocholangiography
- To perform under supervision biliary drainage with one-stick needle systems and needle and guidewire
- To perform under supervision biliary decompression with catheters
- To perform emergency procedures in life-threatening disorders, including cardio-pulmonary resuscitation

## COMPETENCES AND ATTITUDES

- To appropriately select patients for a requested interventional procedure through a review of available history, imaging, laboratory values, and proposed or expected outcomes of the procedure
- To confidently identify features in the history or physical findings that would require pre-procedure assistance from other specialty disciplines, such as cardiology, anaesthesia, surgery or internal medicine
- To confidently identify risk factors from the patient's history, physical or laboratory examinations that indicate potential risk of bleeding, nephrotoxicity, cardiovascular problems, breathing abnormalities, or adverse drug interactions during or after the procedure
- To obtain informed consent after discussion of the procedure with the patient, including a discussion of risks, benefits and alternative therapeutic options
- To choose the best-suited approach for an interventional procedure
- To choose optimal imaging parameters for image-guided interventional procedures
- To apply techniques to reduce exposure doses for interventional procedures, both for the patient and for the radiologist and staff
- To supervise and teach technical staff to ensure that appropriate support is provided for interventional procedures
- To safely apply local anaesthetics for pain management in patients undergoing interventional radiological procedures
- To correctly manage the pre-procedure work-up, including antibiotic regimens, coagulation screening and intravenous fluid replacement for the various radiological interventions
- To correctly manage the monitoring of the patient during the radiological intervention and to recognize abnormalities and physical signs or symptoms that need immediate attention during the procedure
- To correctly manage the aftercare of the various type of radiological interventions, including knowledge of complications, catheter care and ward rounds
- To manage conscious sedation and analgesia during interventional procedures
- To reduce accidental exposure to blood and body fluids in the interventional radiology suite
- To appreciate own limitations and to identify when it is appropriate to obtain assistance in interventional procedures
- To effectively manage and coordinate emergency situations arising from and/or during interventional procedures
- To communicate with patients and their relatives in order to explain the outcome of the interventional procedure
- To perform at multi-disciplinary conferences for patients with potential indications for interventional procedures

## B-II-9 MUSCULOSKELETAL RADIOLOGY

### KNOWLEDGE

- To have an in-depth knowledge of the normal anatomy of all structures relevant to musculoskeletal imaging
- To have an in-depth knowledge of normal skeletal variants that may mimic disease
- To have an in-depth understanding of the development of the immature skeleton
- To have a basic understanding of the embryology of the skeleton
- To list the indications, contraindications and potential hazards (especially radiation hazards) of procedures and techniques relevant to musculoskeletal disease and trauma
- To have a basic clinical knowledge of medical, surgical and pathological conditions as well as pathophysiology related to the musculoskeletal system
- To describe the typical imaging features and clinical manifestations of musculoskeletal disease and trauma, as demonstrated by conventional radiography, CT, MRI, arthrography, radionuclide investigations and ultrasound
- To discuss differential diagnoses relevant to the clinical presentation and imaging appearance of musculoskeletal disease and trauma

### TRAUMA – ACUTE AND CHRONIC

- To list the types and general classifications of fractures and dislocations
- To describe the typical imaging features and basic clinical features of fractures and dislocations in the adult skeleton
- To describe the typical imaging features and basic clinical features of fractures and dislocations in the immature skeleton
- To describe the typical imaging features and basic clinical features of articular fractures and dislocations including chondral and osteochondral lesions and osteochondritis dissecans
- To describe the typical imaging features and basic clinical features of healing and complications of fractures and dislocations, including delayed union, non-union, avascular necrosis, reflex sympathetic dystrophy / complex regional pain syndrome, and myositis ossificans
- To describe the typical imaging features and basic clinical features of stress fractures, including fatigue and insufficiency fractures
- To describe the typical imaging features and basic clinical features of avulsion fractures
- To describe the typical imaging features, imaging strategies and basic clinical features of pathological, and non accidental injury
- To describe the typical imaging features and basic clinical features of skull and facial bone fractures
- To describe the typical imaging features and basic clinical features of spinal fractures, including spondylolysis

- To describe the typical imaging features and basic clinical features of fractures and dislocations of the shoulder girdle, including sternoclavicular and acromioclavicular dislocations, clavicular fractures, scapular fractures, and shoulder dislocation/instability
- To describe the typical imaging features and basic clinical features of fractures and dislocations of the upper limb including humeral fractures, elbow fractures and dislocations, proximal and distal forearm fractures and dislocations, wrist joint fractures/dislocations, and hand fractures and dislocations
- To describe the typical imaging features and basic clinical features of fractures and dislocations of the pelvis including associated soft tissue injuries
- To describe the typical imaging features and basic clinical features of fractures and dislocations of lower limb including hip fractures and dislocations, femoral fractures, tibial and fibular fractures (including the ankle joint), hindfoot fractures, tarso-metatarsal fractures and dislocations and forefoot fractures and dislocations
- To describe the typical imaging features and basic clinical features of soft tissue injuries of the shoulder, including rotator cuff injuries, glenoid labrum injuries and biceps tendon injuries
- To describe the typical imaging features and basic clinical features of soft tissue injuries of the wrist including injuries of the triangular fibrocartilage complex
- To describe the typical imaging features and basic clinical features of soft tissue injuries of the knee, including meniscal injury, cruciate ligament injury, and collateral ligament injury
- To describe the typical imaging features and basic clinical features of soft tissue injuries of the ankle including injuries of the principal tendons and ligaments

## INFECTIONS

- To describe the typical imaging features and basic clinical features of acute, subacute and chronic osteomyelitis of the appendicular skeleton and of the spine
- To describe the typical imaging features and basic clinical features of post-traumatic and postoperative osteomyelitis
- To describe the typical imaging features and basic clinical features of soft tissue injuries of the tuberculosis infections of the musculoskeletal system
- To describe the typical imaging features and basic clinical features of infections of the spine
- To describe the typical imaging features and basic clinical features of infections of the appendicular skeleton
- To describe have a basic understanding of the imaging features of rarer infections (e.g. leprosy, brucellosis)
- To describe the typical imaging features and basic clinical features of infections with more common parasites worldwide (e.g. echinococcus)
- To describe the typical imaging features and basic clinical features of soft tissue infections
- To describe the typical imaging features and basic clinical features of HIV-associated infections



## TUMOURS AND TUMOUR-LIKE LESIONS

- To understand and describe the typical imaging features, principles of tumour characterisation and staging of bone-forming tumours including osteoma and bone islands, osteoid osteoma and osteoblastoma and osteosarcoma (typical and common variants)
- To understand and describe the typical imaging features, principles of tumour characterisation and staging of cartilage-forming tumours including osteochondroma, enchondroma, chondroblastoma, chondromyxoid fibroma, and chondrosarcoma (central and peripheral)
- To understand and describe the typical imaging features, principles of tumour characterisation and staging of tumours of fibrous origin including fibrous cortical defects and non-ossifying fibroma, fibrous dysplasia, fibrosarcoma and malignant fibrous histiocytoma
- To understand and describe the typical imaging features, principles of tumour characterisation and staging of haematopoietic and reticuloendothelial tumours including giant cell tumour, Langerhans cell histiocytosis, malignant round cell tumours (Ewing's sarcoma, lymphoma and leukaemia), myeloma and plasmocytoma
- To understand and describe the typical imaging features, principles of tumour characterisation and staging of tumour-like lesions including simple bone cysts and aneurismal bone cysts
- To understand and describe the typical imaging features, principles of tumour characterisation and staging of metastases
- To confidently recognize "don't touch" lesions
- To understand and describe the typical imaging features, principles of tumour characterisation and staging of chordoma
- To understand and describe the typical imaging features, principles of tumour characterisation and staging of adamantinoma
- To understand and describe the typical imaging features, principles of tumour characterisation and staging of tumours of fat origin, including lipoma and liposarcoma
- To understand and describe the typical imaging features, principles of tumour characterisation and staging of tumours of neural origin including neurofibroma and schwannoma
- To understand and describe the typical imaging features, principles of tumour characterisation and staging of tumours of vascular origin, including haemangioma
- To understand and describe the typical imaging features, principles of tumour characterisation and staging of soft tissue sarcomas

## HAEMATOLOGICAL DISORDERS

- To describe the imaging features and basic clinical features of haemoglobinopathies including sickle cell disease and thalassaemia
- To describe the imaging features and basic clinical features of myelofibrosis

## METABOLIC, ENDOCRINE AND TOXIC DISORDERS

- To describe the imaging features and basic clinical features of rickets and osteomalacia
- To describe the imaging features and basic clinical features of primary and secondary hyperparathyroidism (including chronic renal failure)
- To describe the imaging features and basic clinical features of osteoporosis (including basic concepts of bone mineral density measurements), and fluorosis

## JOINTS

- To have an in-depth knowledge of the imaging features and clinical features of degenerative disease of the spine, disc and facet joints
- To have an in-depth knowledge of the imaging features and clinical features of degenerative disease of the peripheral joints
- To have an in-depth knowledge of the imaging features and clinical features of inflammatory joint disease, including rheumatoid arthritis, juvenile rheumatoid arthritis, ankylosing spondylitis, psoriatic arthritis, enteropathic arthropathies, and infective arthritis (pyogenic and tuberculous)
- To describe the imaging features and basic clinical features of crystal arthropathies, including pyrophosphate arthropathy, hydroxyapatite deposition disease, and gout
- To describe the imaging features and basic clinical features of masses of the joints, including, ganglion, synovial chondromatosis, and pigmented villonodular synovitis
- To describe the imaging features and basic clinical features of neuroarthropathy, including diabetic foot, Charcot's joints, Pseudo-Charcot joint (steroid-induced)
- To describe the imaging features and basic clinical features of complications of prosthetic joint replacement (hip and knee)

## CONGENITAL, DEVELOPMENTAL AND PAEDIATRIC

- To describe the imaging features and basic clinical features of congenital disorders of the spine, including scoliosis (congenital and idiopathic), and dysraphism
- To describe the imaging features and basic clinical features of congenital disorders of the shoulder, including Sprengel's deformity
- To describe the imaging features and basic clinical features of congenital disorders of the hand and wrist, including Madelung deformity (idiopathic and other causes)
- To describe the imaging features and basic clinical features of congenital disorders of the hip, including developmental dysplasia, irritable hip, Perthes disease, slipped upper femoral epiphysis
- To describe the imaging features and basic clinical features of femoroacetabular impingement
- To describe the imaging features and basic clinical features of congenital disorders of the ankle and foot
- To describe the imaging features and basic clinical features of congenital tarsal coalition
- To describe the imaging features and basic clinical features of bone dysplasias
- To describe the imaging features and basic clinical features of congenital disorders of multiple epiphyseal dysplasia

- To describe the imaging features and basic clinical features of congenital disorders of achondroplasia
- To describe the imaging features and basic clinical features of congenital disorders of osteogenesis imperfecta
- To describe the imaging features and basic clinical features of congenital disorders of the sclerosing disorders of the bone, including osteopetrosis, melorheostosis and osteopoikilosis
- To describe the imaging features and basic clinical features of tumour-like lesions in the paediatric age group, including diaphyseal aclasis and Ollier's disease
- To describe the imaging features and basic clinical features of the musculoskeletal manifestations of neurofibromatosis

## MISCELLANEOUS

- To describe the imaging features and basic clinical features of Paget's disease
- To describe the imaging features and basic clinical features of sarcoidosis
- To describe the imaging features and basic clinical features of hypertrophic osteoarthropathy
- To describe the imaging features and basic clinical features of transient or regional migratory osteoporosis
- To describe the imaging features and basic clinical features of osteonecrosis
- To describe the principles of characterisation of soft tissue calcification/ossification

## SKILLS

- To choose the most appropriate imaging examination according to the clinical problem in musculoskeletal imaging
- To choose the most suitable contrast material and its optimal use according to the imaging technique and the clinical problem in musculoskeletal imaging
- To perform dynamic functional studies of the spine and joints
- To perform a correct positioning for radiography of the spine and of the extremities including special views
- To perform ultrasound of the musculoskeletal system
- To perform image-guided biopsies in the musculoskeletal system in easy cases
- To observe and/or perform under supervision image-guided biopsies in the musculoskeletal system in more complex cases
- To confidently plan a CT examination of the musculoskeletal system and to tailor it to the individual situation, with a dose as low as reasonably achievable
- To confidently plan an MRI examination of the musculoskeletal system and to tailor it to the individual situation in regard to the potential use of intravenous contrast medium and spatial resolution
- To perform contrast media applications in various joints, including the hip, shoulder and wrist for MR arthrography or CT arthrography
- To observe and/or to perform under supervision discography, facet joint injections and vertebroplasty
- To observe and/or to perform under supervision image-guided bone biopsy and drainage of the musculoskeletal system
- To confidently perform proper post-processing tasks of musculoskeletal imaging studies, including multi-planar reformations (MPR), maximum intensity projections (MIP), minimum intensity projections (MinIP), and fusion images

## COMPETENCES AND ATTITUDES

- To confidently justify diagnostic imaging examinations and/or interventional procedures of the musculoskeletal system
- To confidently choose the best-suited method for evaluating disorders of the musculoskeletal system
- To communicate with the patient in order to obtain informed consent prior to diagnostic imaging and interventional procedures of the musculoskeletal system
- To confidently choose optimal imaging parameters for radiographic, ultrasonographic, CT and MRI examinations of the musculoskeletal system
- To confidently apply techniques to reduce exposure doses for radiographic and CT examinations of the musculoskeletal system
- To confidently design imaging protocols and standard operating procedures for CT examinations of the musculoskeletal system, including the appropriate application of intravenous contrast, positioning, spatial and temporal resolution
- To confidently design imaging protocols and standard operating procedures for MRI examinations of the musculoskeletal system, positioning, including the appropriate application of intravenous contrast, spatial and temporal resolution
- To supervise and teach technical staff to ensure that appropriate images of the musculoskeletal system are obtained
- To confidently judge the quality of imaging examinations in musculoskeletal imaging and to devise strategies to improve image quality
- To confidently interpret and report radiographs, ultrasonographic examinations, osteodensitometric studies, CT studies and MRI examinations of the musculoskeletal system
- To report oncological studies of the musculoskeletal system according to international standards (RECIST, WHO) applicable to the specific situation
- To appreciate own limitations and to identify when it is appropriate to obtain assistance in interpreting and reporting images of the musculoskeletal system
- To confidently identify urgent and/or unexpected findings in imaging examinations of the musculoskeletal system and to communicate these timely and properly
- To communicate with patients and their relatives in order to explain their imaging findings of the musculoskeletal system
- To perform at multi-disciplinary conferences and tumour boards for diseases of the musculoskeletal system

## B-II-10 NEURORADIOLOGY

### KNOWLEDGE

#### NORMAL ANATOMY

- To have an in-depth understanding of the normal anatomy of the brain and spine including the skull, skull base, brain, spine, spinal cord and peripheral nervous system
- To confidently detect and describe normal imaging findings of the brain and spine on X-ray, ultrasound, CT and MRI
- To confidently delineate and describe the skull, skull base, and spine on conventional radiography
- To confidently delineate the cortex, white matter, basal ganglia, ventricles, cisterns and cranial nerves on CT and/or MRI of the brain
- To confidently delineate the vertebral bodies, spinal canal, intervertebral discs, dural sac, spinal cord and cauda equina on CT and/or MRI of the spine
- To confidently delineate the aortic arch, carotid and vertebral arteries, intracranial arteries and the circle of Willis, spinal and spinal cord vascularisation on angiography
- To describe normal variants of the brain and spine and differentiate these from pathology

#### CONGENITAL AND DEVELOPMENTAL ABNORMALITIES

- To describe the imaging features of malformations of cortical development, including focal cortical dysplasia, polymicrogyria, heterotopia (subependymal, focal subcortical, laminar), lissencephaly / pachygyria, (hemi)megalencephaly, microlissencephaly, schizencephaly
- To describe the imaging features of agenesis and dysgenesis of the corpus callosum and of holoprosencephaly (lobar, alobar, semilobar)
- To describe the imaging features of hindbrain and posterior fossa malformations, including the Chiari malformations, the Dandy Walker spectrum and the molar tooth malformations (including Joubert syndrome)
- To describe the imaging features of white matter injury of the premature brain / periventricular leukodystrophy (PVL)
- To describe the imaging features of hypoxic ischemic encephalopathy of the mature infant after severe acute asphyxia
- To describe the imaging features of hypoxic ischemic encephalopathy of the mature infant after prolonged partial hypoxia
- To describe the neuro-imaging features, extracranial manifestations, diagnostic criteria and clinical features of tuberous sclerosis, Sturge-Weber diseases, neurofibromatosis type I and II, and other common phakomatoses
- To describe the common imaging features of segmental vascular syndromes
- To describe the common imaging features of inherited metabolic conditions and leukodystrophies

## NEUROVASCULAR

- To list the major types of stroke
- To describe the relevance of the “time is brain” approach to the imaging evaluation of patients with stroke
- To describe comprehensive stroke evaluation parameters for MRI and CT in patients with stroke, including diffusion-weighted imaging, perfusion-imaging, CTA and MRA
- To list the perfusion parameters relevant for stroke imaging and to describe their relevance and limitations
- To list and describe the main neuroradiological interventions in patients with ischaemic stroke
- To describe the diagnostic and therapeutic approach in patients with ischemic strokes of the posterior circulation / basilar artery occlusion
- To describe interventional approaches to intracranial stenoses
- To describe the imaging features, relevant clinical features and imaging algorithm in patients with venous stroke / intracranial venous thrombosis
- To describe the imaging and clinical features in patients with subarachnoid hemorrhage (SAH)
- To describe the typical imaging evaluation algorithm in patients with spontaneous SAH
- To list the major complications and describe their respective imaging features in patients with SAH
- To describe the imaging features and relevant hemodynamic parameters in patients with vasospasms
- To differentiate atypical and typical intracerebral haemorrhages
- To list the major causes for atypical and typical intracerebral haemorrhages
- To describe the imaging algorithms in patients with atypical and typical intracerebral haemorrhages
- To list the different types of intracranial and extracranial vascular malformations
- To describe the imaging features and therapeutic approaches in patients with intracranial vascular malformations including arteriovenous malformations, dural arterio-venous fistulas, cavernous haemangiomas and carotid-cavernous sinus fistulas
- To describe the imaging features, differential diagnoses and relevance of developmental venous anomalies
- To describe the imaging features, differential diagnoses and relevance of capillary teleangiectasias
- To describe the imaging features of the different types of intracranial aneurysms: saccular, dissecting, fusiform, giant, infectious
- To describe the imaging features of intra/extracranial arterial dissections
- To describe the imaging features of posterior reversible encephalopathy syndrome
- To describe cerebrovascular lesions related to arterial hypertension
- To describe the typical imaging evaluation and features of brain death
- To describe the imaging and clinical features in patients with venous occlusive disease
- To describe the imaging features, differential diagnoses and relevance of cavernous malformations
- To describe the imaging features of non-atherosclerotic, non-hypertensive cerebrovascular diseases (Moya-Moya, CADASIL)

## NEUROTRAUMA

- To list the typical imaging algorithms for patients with acute traumatic injury to the brain
- To describe the typical imaging features and basic clinical features in patients with epidural hematoma
- To describe the typical imaging features and basic clinical features in patients with subdural hematoma
- To describe the typical imaging features and basic clinical features in patients with traumatic subarachnoidal hemorrhage
- To describe the typical imaging features and basic clinical features in patients with traumatic contusions of the brain parenchyma
- To describe the typical imaging features and warning signs for elevated intracranial pressure
- To describe the typical imaging features of fractures of the skull and skull base including the temporal bone
- To describe the typical imaging features and clinical features in children with non-accidental injury
- To describe the typical imaging features of vascular traumatic injury of the intra- and extracranial vessels

## INTRACRANIAL TUMOURS

- To list the most common intracranial tumours
- To describe the typical imaging manifestations of intracranial metastases of various primary tumours
- To list the different WHO grade of astrocytomas/gliomas
- To describe the imaging features and basic clinical features of astrocytomas
- To describe the imaging features and basic clinical features of pilocytic astrocytomas
- To describe the imaging features, basic clinical features, location and association of giant cell astrocytomas
- To list the typical imaging features and locations of the various forms of brain stem tumours
- To describe the imaging features and basic clinical features of optic pathway gliomas
- To describe the imaging features and basic clinical features of ependymomas
- To describe the imaging features and basic clinical features of medulloblastomas
- To describe the basic imaging features of atypical teratoid and rhabdoid tumors (ATRT)
- To describe the imaging features and basic clinical features of plexus papilloma and plexus carcinoma
- To describe the imaging features and basic clinical features of primary and secondary lymphoma of the brain
- To describe the imaging features, basic clinical features and differential diagnosis of sellar and perisellar tumours
- To describe the imaging features and basic clinical features of pituitary microadenomas and macroadenomas
- To describe the imaging features and basic clinical features of tumours of the pineal gland
- To describe the imaging features and basic clinical features of meningiomas
- To list imaging features of atypical meningiomas/meningiosarcomas/hemangiopericytomas
- To list the basic imaging features and location of tuber cinereum hamartoma
- To list the basic imaging features of Lhermitte-Duclos syndrome and its association with Cowden syndrome
- To describe the imaging features and basic clinical features of oligodendroglioma
- To describe the imaging features of ganglioglioma, gangliocytoma and dysembryoplastic neuroepithelial tumour (DNET)
- To describe the imaging features and basic clinical features of schwannomas of the cranial nerves including vestibular schwannoma/"acoustic neuroma", trigeminal schwannoma and facial nerve schwannoma

- To describe the imaging features of chordoma of the clivus
- To describe the imaging features and to differentiate tumours of the orbits and temporal bone
- To describe the imaging features and to differentiate tumours of the skull and skull base

## NEUROINFLAMMATORY, NEUROINFECTIOUS AND NEURODEGENERATIVE DISORDERS

- To describe the typical age-related changes to the brain
- To describe the typical and atypical imaging features and clinical features of multiple sclerosis (MS)
- To differentiate the appearance of demyelinating white matter lesions from age-related white matter changes
- To describe the typical imaging features and clinical features of patients with dementia of the Alzheimer type, as well as of other forms of dementia
- To have a basic understanding of the imaging features in Parkinson's disease and in atypical Parkinson syndromes, including multi-system atrophy and progressive supranuclear palsy
- To describe the typical CNS imaging features and basic clinical features of Morbus Wilson
- To describe the imaging features and basic clinical features of acute and chronic hepatic encephalopathy
- To describe the imaging features and basic clinical features of exogenous toxic and acquired metabolic conditions (osmotic demyelination syndrome, hyper/hypoglycemia, iron and copper metabolic disorders, ethanol abuse)
- To have an in-depth understanding of the typical and atypical imaging features of herpes simplex virus (HSV) infections of the brain, and understand the therapeutic concepts and urgency of HSV infections of the brain
- To describe the imaging features and the limitations of imaging in patients with meningitis
- To list the typical complications of meningitis and to describe their imaging features
- To describe the typical imaging features and basic clinical features of the different stages of intracranial abscess formation
- To describe the typical imaging features and basic clinical features of tuberculous meningitis and intracranial Tuberculomas
- To have a basic understanding of congenital infections of the brain including toxoplasmosis, CMV, rubella and HSV
- To describe the typical imaging features and basic clinical features of sarcoidosis
- To describe the typical intracranial imaging features and basic clinical features of CNS vasculitis
- To describe the typical intracranial imaging features and basic clinical features of HIV infection of the brain
- To describe the typical intracranial imaging features and basic clinical features of typical complications of HIV infections
- To describe the typical imaging features and basic clinical features of prion infections
- To describe the typical imaging features and basic clinical features of fungal infections
- To describe the typical imaging features and causes of therapy associated changes to the brain, e.g. after radiation therapy and after chemotherapy
- To describe the typical imaging features of paraneoplastic syndromes involving the central nervous system



## HYDROCEPHALUS

- To have a basic understanding of the production, flow and resorption of CSF
- To list and to differentiate the different types of hydrocephalus and their respective causes
- To describe the typical imaging features and clinical features of normal pressure hydrocephalus
- To describe the typical imaging features, causes and clinical features of non-communicating hydrocephalus
- To describe the typical imaging features, causes and clinical features of CSF malabsorption
- To have a basic understanding of the production, flow and resorption of CSF
- To describe the typical imaging features and list the major causes of aqueductal stenosis
- To describe the method of imaging-based flow assessment of the CSF
- To have a basic understanding of the different therapeutic approaches to hydrocephalus, including shunt placement and third ventriculostomy

## SPINE

- To describe the imaging features and basic clinical features of spinal malformations including spina bifida aperta, spina bifida occulta, meningocele, dermal sinus, split cord malformations, scoliosis
- To differentiate stable and unstable fractures of the spine
- To differentiate between benign and malignant vertebral compression fractures
- To describe the imaging features of myelopathy and to list its common causes
- To describe the typical imaging features of spinal metastases including the criteria for cord compression
- To describe the typical imaging features and clinical features in spinal cord ischemia
- To list the most common intraspinal tumours
- To describe the imaging features and basic clinical features of spinal cord tumours (ependymoma, astrocytoma, haemangioblastoma)
- To describe the imaging features and basic clinical features of spinal meningiomas
- To describe the imaging features and basic clinical features of transverse myelitis (TM), acute disseminated encephalomyelitis (ADEM), neuromyelitis optica (NMO)
- To describe the imaging features and basic clinical features of spinal manifestations of MS
- To describe the imaging features and basic clinical features of infectious diseases of the spine and spinal cord including spondylodiscitis
- To describe the imaging features and basic clinical features of spinal vascular malformations
- To describe the imaging features and basic clinical features of syrinx formation and hydromyelia
- To describe the imaging features of chordomas of the spine
- To have an in-depth knowledge of the imaging features of degenerative diseases of the spine disc and facet joints
- To describe percutaneous and endovascular interventional procedures of the spine/spinal cord

## EPILEPSY

- To list the major causes of seizures in pediatric and adult population
- To describe the typical imaging evaluation algorithm in patients with seizures
- To describe the imaging features of mesial temporal sclerosis
- To describe the imaging features of status epilepticus

## PERIPHERAL NERVOUS SYSTEM

- To describe the typical imaging evaluation algorithm and features of brachial plexopathy
- To describe the typical imaging evaluation algorithm and features of lumbosacral plexopathy
- To describe the typical imaging evaluation algorithm in patients with entrapment neuropathies
- To describe the imaging features of tumoural and inflammatory lesions of the peripheral nerves

## SKILLS

- To choose the most appropriate imaging examination according to the clinical problem in neuroradiology
- To choose an appropriate interventional procedure (endovascular or percutaneous) according to the clinical problem in neuroradiology
- To choose the most suitable contrast material and its optimal use according to the imaging technique and the clinical problem in neuroradiology
- To observe and/or perform under supervision ultrasound of brain in the infant
- To observe and/or perform under supervision Doppler sonography of the intracranial vessels
- To observe and/or perform under supervision diagnostic neuroangiography
- To observe and/or perform under supervision intraarterial thrombolysis in patients with ischaemic stroke
- To observe and/or perform under supervision mechanical recanalisation in patients with ischemic stroke
- To observe and/or perform under supervision neurointerventional therapy in patients with acute basilar artery occlusion
- To observe and/or perform under supervision endovascular treatment of intracranial aneurysms
- To observe and/or perform under supervision spinal angiography
- To observe and/or perform under supervision disk, vertebral and facet interventional procedures included discography and biopsy
- To observe and/or to perform under supervision discography, facet joint injections and vertebroplasty
- To confidently plan a CT examination of the brain and spine and to tailor it to the individual situation, with a dose as low as reasonably achievable
- To plan CT perfusion and MR perfusion studies of the brain including the volume and rate of application of contrast medium and the number of acquisitions
- To confidently plan an MRI examination of the brain and spine and to tailor it to the individual situation in regard to the potential use of intravenous contrast medium and spatial resolution
- To plan and perform advanced CT and MRI examinations including perfusion CT and MR, diffusion tensor imaging, functional MR imaging, and proton MR spectroscopy
- To confidently perform proper post-processing tasks of neuroradiological studies, including multi-planar reformations (MPR), maximum intensity projections (MIP), minimum intensity projections (MinIP), DTI, functional MRI and fusion images

## COMPETENCES AND ATTITUDES

- To confidently justify diagnostic imaging examinations and/or interventional procedures of the brain, skull, skull base, spine, spinal cord and peripheral nervous system
- To confidently choose the best-suited method for evaluating disorders of the brain, skull, skull base, spine, spinal cord and peripheral nervous system
- To communicate with the patient in order to obtain informed consent prior to diagnostic imaging and interventional procedures of the brain, skull, skull base, spine, spinal cord and peripheral nervous system
- To confidently choose optimal imaging parameters for radiographic, ultrasonographic, CT and MRI examinations of the brain, skull, skull base, spine, spinal cord and peripheral nervous system
- To confidently apply techniques to reduce exposure doses for radiographic and CT examinations of the brain, skull, skull base, spine
- To design a time-saving imaging algorithm and to define standard operating procedures for imaging patients with stroke
- To confidently perform and interpret a comprehensive imaging evaluation in patients with stroke
- To confidently design imaging protocols and standard operating procedures for CT examinations of the brain, skull, skull base, spine, spinal cord, peripheral nervous system, including the appropriate application of intravenous contrast, positioning, spatial and temporal resolution
- To confidently design imaging protocols and standard operating procedures for MRI examinations of the brain and spine, including the appropriate application of intravenous contrast, spatial and temporal resolution
- To supervise and teach technical staff to ensure that appropriate images of the brain, skull, skull base, spine, spinal cord, peripheral nervous system are obtained
- To confidently judge the quality of imaging examinations in neuroradiology and to devise strategies to improve image quality
- To confidently interpret and report radiographs, ultrasonographic examinations, CT studies and MRI examinations of the brain and spine
- To report oncological studies of the brain according to international standards applicable to the specific situation
- To appreciate own limitations and to identify when it is appropriate to obtain assistance in interpreting and reporting images of the brain, skull, skull base, spine, spinal cord, peripheral nervous system
- To confidently identify urgent and/or unexpected findings in imaging examinations of the brain, skull, skull base, spine, spinal cord, peripheral nervous system and to communicate these timely and properly
- To communicate with patients and their relatives in order to explain their imaging findings of the brain and spine
- To participate in and/or conduct multi-disciplinary conferences, vascular boards, and tumour boards for diseases of the brain, skull, skull base, spine, spinal cord, peripheral nervous system

## B-II-11 ONCOLOGIC IMAGING

### KNOWLEDGE

#### CANCER: BIOLOGY & TREATMENT

- To develop an understanding of oncogenesis, angiogenesis, lymphangiogenesis and metastasis including genomics and proteomics
- To understand the principles of treatment including surgery, locoregional therapies, chemotherapy (including systemic and targeted therapies; adjuvant and neoadjuvant) and radiotherapy (conventional, brachytherapy, and stereotactic)
- To develop a core knowledge of the biology of different tumour types, particularly the most common cancers: lung, breast, colorectal, and prostate.
- To understand the treatment strategies of different tumour types, particularly the most common cancers: lung, breast, colorectal, and prostate
- To describe the acute and chronic complications of oncologic treatment and their imaging features

#### IMAGING TECHNIQUES IN ONCOLOGIC IMAGING

- To describe indications and contraindications for the various imaging examinations in oncologic imaging for staging and response assessment
- To describe the most appropriate imaging examination for oncologic imaging according to the clinical problem: ultrasound, CT, MRI, and hybrid techniques (PET-CT, PET-MRI, SPECT-CT)
- To understand the strengths and limitations of each imaging technique in oncologic imaging
- To understand the role of endocavitary/endoscopic US techniques for tumour characterization and staging
- To recommend appropriate endocavitary/endoscopic US investigations
- To describe the best contrast material and its optimal use according to the imaging technique and the clinical problem in oncologic imaging
- To understand the relative costs of the various imaging examinations in oncologic imaging
- To know the radiation burden and risks of different investigations in oncologic imaging
- To describe techniques for post-processing images in view of obtaining reformat, MIP, MinIP, vessel analysis, 3D analysis, including endoluminal reconstructions, fusion images, as well as acquisition and treatment of functional studies in oncologic imaging
- To have detailed knowledge of basic US, CT, MRI, nuclear medicine and PET-CT techniques, findings and pitfalls in diagnosis in those cancers frequently referred for imaging
- To understand the indications for functional imaging techniques in oncologic imaging

## PRINCIPLES OF ADVANCED IMAGING TECHNIQUES AND CONTRAST AGENTS IN ONCOLOGIC IMAGING

- To understand the principles of PET-CT for oncologic imaging
- To develop knowledge of the most important PET tracers with fluorine 18 or carbon 11 including FDG, FLT, F-MISO, choline, acetate
- To describe PET imaging protocols, methods of PET image analysis and data processing and possible pitfalls and limitations of this technique in oncologic imaging
- To understand the principles of advanced MRI techniques used in oncologic imaging including: Dynamic contrast-enhanced (DCE) MRI, Diffusion-weighted imaging (DWI), Spectroscopy using <sup>1</sup>H, <sup>31</sup>P, <sup>13</sup>C, Targeted contrast agents and fMRI (BOLD)
- To understand the principles of advanced CT techniques including dynamic contrast enhanced CT (perfusion CT) in oncologic imaging
- To understand the principles of contrast-enhanced ultrasound (CEUS) in oncologic imaging
- To describe the imaging protocols and methods of image analysis and data processing for the different MRI, CT and US techniques in oncologic imaging

## CANCER STAGING

- To describe the imaging anatomy and the pathways of spread for the common cancer types
- To describe the common staging systems: TNM and clinical staging classification and to know their limitations
- To describe the application of imaging techniques including ultrasound, computed tomography, magnetic resonance imaging, nuclear medicine and positron emission tomography for cancer staging
- To have an understanding of the appropriate choice of imaging techniques and/or the appropriate sequence of imaging techniques in the investigation of specific clinical problems in oncologic imaging
- To have an appreciation of common imaging 'false positives' and 'false negatives' in cancer staging, and the role of different imaging techniques for lesion characterisation
- To know the national and international guidelines for staging common cancer types

## TREATMENT PLANNING IN ONCOLOGIC IMAGING

- To understand the role of imaging in treatment planning e.g. surgery, radiotherapy
- To have awareness of national and international guidelines in treatment planning in oncologic imaging

## CANCER RESPONSE ASSESSMENT & CLINICAL TRIALS

- To describe the principles of response assessment and an appreciation of the advantage and limitations of the different response criteria e.g. RECIST, combined size and enhancement criteria, PET criteria for evaluation of lymphoma
- To understand the concept of clinical trials, including main endpoints for evaluation of treatments like response rate, disease control rate, time to progression, disease-free and progression-free survival, best overall response
- To understand the concepts of the following: baseline examination, nadir, tumour response, tumour progression, stable disease, target lesion, non-target lesions, new lesions, pseudoprogression
- To understand the advantages and limitations of each imaging method for response evaluation (ultrasound, CT, MRI, nuclear medicine and PET)
- To understand the role of advanced techniques in response assessment: DCE-MRI, DW-MRI, MR-Spectroscopy, PET-CT, Perfusion CT
- To understand the challenges of advanced imaging biomarker development in clinical trials: generalizability, standardization, QA, QC
- To have awareness of national and international guidelines in cancer response assessment and clinical trials

## CANCER SCREENING & SURVEILLANCE

- To understand the principles of screening and the organisation of screening using breast, lung and colorectal cancer as core examples and to have awareness of national and international guidelines in this field
- To appreciate the main advantages and drawbacks of a screening programme
- To describe the role for different imaging techniques in surveillance in different cancer types
- To describe the patterns of recurrence in common cancers
- To describe the role of imaging in assessing suspected disease recurrence, and the advantages and limitations of different techniques
- To understand the potential of advanced techniques for surveillance: whole body MRI, PET/CT with different tracers

## INTERVENTIONAL ONCOLOGY

- To describe the basic principles of safe interventional technique; the anatomy relevant to the procedure; recognised complications of the procedures
- To be familiar with the wide range of interventional techniques used in oncological radiology
- To describe the common procedures including for percutaneous fine needle aspiration, biopsy or drainage using image-guidance
- To know the potential risks and complications of common procedures in interventional oncology
- To be aware of the pharmacological actions of the agents used in analgesia and sedation and the necessary monitoring required to perform this safely
- To describe the processes and actions required in intermediate life support and management of anaphylaxis

## SKILLS

- To justify, protocol, conduct and supervise oncological imaging examinations to a high standard
- To confidently tailor examinations appropriately to the clinical question in oncologic imaging
- To confidently interpret all images relevant in the diagnosis, staging, assessment of response and detection of recurrent disease of the common cancers
- To develop resources to be able to diagnose, stage, assess response of unusual tumour types using all imaging modalities
- To accurately assess response to treatment according to recognised objective response criteria in oncologic imaging
- To advise on the appropriate diagnostic imaging and follow-up protocols for different tumour types
- To plan effective imaging pathways for the common cancers
- To confidently discuss the appropriate imaging strategies in oncologic imaging with clinicians within a multidisciplinary setting
- To communicate effectively with patients and professional colleagues in the interdisciplinary oncological team
- To provide clinicians with optimised images which may aid surgical management or treatment planning including the role of imaging in radiotherapy planning and treatment
- To competently work with US, CT and MRI-guided interventions and where appropriate, fluoroscopic imaging
- To undertake the following procedures under supervision: US-guided biopsy of masses and lymph nodes; CT-guided biopsy of masses (retroperitoneal, pelvic side-wall, thoracic and lymph nodes); Drainage of collections

## COMPETENCIES AND ATTITUDES

- **To conduct good clinical care:** To be aware of the limits of personal knowledge and to know when to seek further information or help
- **To maintain good medical practice:** To keep the knowledge base up to date and be able to discuss current medical practice with colleagues and patients
- **To work in partnership with patients:** To be aware of different levels of patient understanding and personality types, to explain diagnostic and therapeutic radiology procedures effectively, and to exhibit a flexible approach taking into account different learning styles and expectations of patients
- **To demonstrate good team working skills:** To understand the value of team working (multidisciplinary teams) and to demonstrate good communication with professional colleagues
- **To assure and improve the quality of care:** To be able to describe an effective clinical governance approach and to participate in clinical governance processes e.g. clinical audit, guidelines development
- **To develop teaching competencies:** To understand the principles of teaching and learning, and conduct teaching sessions in a quality assured training programme and develop competence as a clinical supervisor

## B-II-12 PAEDIATRIC RADIOLOGY

### KNOWLEDGE

- To have an in-depth understanding of developmental anatomy during childhood
- To describe normal variants in childhood that may mimic disease
- To have a basic understanding of embryology as applied to paediatric diseases
- To have a basic understanding of the various stages of embryonic and fetal development and their respective appearance on US and MR imaging
- To understand and describe the principles guiding the construction of a child-friendly environment
- To understand the ALARA principle and dose consideration and their application in paediatric patients
- To list and describe imaging guideline algorithms specific to children
- To have an in-depth knowledge of indications and contraindications for contrast media within the paediatric population including neonates

### BRAIN AND SPINE

- To describe the imaging features and basic clinical features of the main congenital malformations of the brain (for details, see B-II-9 Neuroradiology, Congenital and developmental abnormalities)
- To describe the imaging features, causes and basic clinical features of hydrocephalus in infants, children and adolescents
- To describe the imaging features, causes and basic clinical features of subependymal and intraventricular haemorrhage in infants
- To describe the imaging features, causes and basic clinical features of periventricular leukomalacia
- To have an in-depth knowledge of the imaging features and basic clinical features of elevated intracranial pressure in infants, children and adolescents
- To have an in-depth knowledge of the imaging features and basic clinical features of brain tumours in infants, children and adolescents
- To have an in-depth knowledge of the imaging features and basic clinical features of head trauma in infants, children and adolescents
- To describe the imaging features and clinical features of non-accidental trauma in infants, children and adolescents
- To have an in-depth knowledge of the imaging features and basic clinical features of intracranial infections (including antenatal infections) in infants, children and adolescents
- To describe the imaging features, causes and basic clinical features of intracranial ischaemia / stroke in infants, children and adolescents
- To have an in-depth knowledge of the imaging features and basic clinical features of pituitary disease in infants, children and adolescents
- To describe the imaging features and basic clinical features of spinal malformations including spina bifida aperta, spina bifida occulta, meningomyelocele, dermal sinus, split cord malformations



## HEAD AND NECK

- To describe the imaging features and basic clinical features of the main congenital malformations of the head and neck region including the orbit, the nose, the pharynx, the temporal bone in infants, children and adolescents (for details, see specific chapter in head and neck radiology)
- To describe the imaging features, causes and basic clinical features of inflammatory/infectious disorders of the head and neck region in infants, children and adolescents
- To have an in-depth knowledge of tumours of the head and neck region in infants, children and adolescents
- To have an in-depth knowledge of the imaging features and basic clinical features of traumatic lesions of the head and neck region in infants, children and adolescents
- To describe the imaging features of thyroid diseases in infants, children and adolescents

## CHEST

- To describe the radiographic imaging features of normal thymus and its variants in infants, children and adolescents
- To describe the radiographic imaging features of congenital abnormalities of bronchus and chest (pulmonary sequestration, cystic adenomatoid malformation, lobar emphysema, bronchial atresia) in infants, children and adolescents
- To describe the radiographic imaging features of neonatal respiratory distresses in premature babies and neonates
- To describe the radiographic imaging features of foreign body aspiration in infants, children and adolescents
- To describe the radiographic imaging features of bronchiolitis in infants, children and adolescents
- To describe the radiographic imaging features of cystic fibrosis in infants, children and adolescents
- To describe the radiographic imaging features of chest consolidation, pneumonia and complications of pneumonia in infants, children and adolescents
- To describe the radiographic imaging features of pleural effusions in infants, children and adolescents
- To describe the radiographic imaging features of pneumothorax in infants, children and adolescents
- To describe the radiographic imaging features of congenital pulmonary airway malformations
- To describe the imaging features of infiltrative diseases of the lung in infants, children and adolescents
- To describe the imaging features of complications of metastatic diseases of the lung in infants, children and adolescents
- To describe the imaging features of mediastinal masses (germ-cell tumour, cystic mediastinal masses, lymphadenopathies, lymphoma, neurogenic tumours) in infants, children and adolescents
- To describe the imaging features of congenital diaphragmatic hernia, diaphragm palsy and eventration in infants, children and adolescents

## CARDIOVASCULAR

- To describe the imaging features and basic clinical features of the main congenital malformations of cardiovascular system including aortic arch abnormalities in infants, children and adolescents
- To describe the imaging features, causes and basic clinical features of arterial hypertension in infants, children and adolescents
- To describe the imaging features, causes and basic clinical features of inflammatory / infectious disorders of the cardiovascular system in infants, children and adolescents
- To have an in-depth knowledge of the imaging features and basic clinical features of traumatic lesions of the cardiovascular system in infants, children and adolescents
- To have an in-depth knowledge of the imaging features and basic clinical features of vascular malformations and vascular tumours in infants, children and adolescents

## DIGESTIVE TRACT

- To describe the radiographic imaging features of oesophageal atresia in neonates
- To describe the imaging features of necrotizing enterocolitis in neonates
- To describe the imaging features of pneumoperitoneum in neonates
- To describe the imaging features and basic clinical features of ano-rectal malformations in neonates
- To describe the imaging features of hypertrophic pyloric stenosis in neonates and infants
- To describe the imaging features and basic clinical features of gastrointestinal obstruction in neonates
- To describe the imaging features and basic clinical features of Hirschsprung's disease in neonates, infants, children and adolescents
- To describe the imaging features and basic clinical features of gastro-oesophageal reflux in infants, children and adolescents
- To describe the imaging features and basic clinical features of intestinal malrotations and volvulus in infants, children and adolescents
- To have an in-depth knowledge of the imaging features and clinical features of intestinal intussusception in infants, children and adolescents
- To have an in-depth knowledge of the imaging features and clinical features of appendicitis in infants, children and adolescents
- To describe the imaging features and basic clinical features of peritonitis in neonates, infants, children and adolescents
- To describe the imaging features and basic clinical features of inguinal hernia in infants, children and adolescents
- To describe the imaging features and basic clinical features of inflammatory bowel diseases and the respective complications in infants, children and adolescents
- To describe the imaging features and basic clinical features of blunt abdominal trauma in infants, children and adolescents
- To describe the imaging features and basic clinical features of digestive tract foreign bodies in infants, children and adolescents

- To describe the imaging features and basic clinical features of disorders of the hepatobiliary system (jaundice in infants, biliary atresia, choledochal cyst, benign liver tumours) in infants, children and adolescents
- To describe the evaluation of disorders of the biliary system with US and MRCP in infants, children and adolescents
- To describe the imaging features and basic clinical features of disorders of portal circulation in infants, children and adolescents
- To describe the imaging features and basic clinical features of disorders of the pancreas in infants, children and adolescents
- To describe the imaging features and basic clinical features of disorders of the spleen in infants, children and adolescents

## GENITO-URINARY TRACT

- To list main renal malformations, such as horseshoe kidney, ectopia, or fusion
- To describe the imaging features and basic clinical features of upper and lower urinary tract malformations in infants, children and adolescents
- To describe the imaging features and basic clinical features of urinary tract infection in infants, children and adolescents
- To describe the imaging features of the different grades of vesico-ureteral reflux and urethral anomalies on voiding cysturethrography
- To describe the imaging features and basic clinical features of uretero-hydronephrosis in infants, children and adolescents
- To describe the imaging features and basic clinical features of cystic diseases of the kidneys in infants, children and adolescents
- To describe the imaging features of urolithiasis and nephrocalcinosis in infants, children and adolescents
- To describe the imaging features and basic clinical features of oncologic disorders of the abdomen in infants, children and adolescents, including neuroblastoma, Wilms tumours, hepatoblastoma, Burkitt's lymphoma, with differential diagnosis
- To describe the imaging features and basic clinical features of common disorders of the adrenal glands in infants, children and adolescents
- To describe the imaging features and basic clinical features of sexual development disorders in neonates and infants
- To describe the imaging features and basic clinical features of pubertal development disorders in infants and adolescents
- To describe the imaging features and basic clinical features of common gynaecological disorders (malformations, ovarian cysts and tumours) in girls
- To describe the imaging features and basic clinical features of common disorders of the testis and scrotum in boys

## MUSCULOSKELETAL

- To describe the imaging features and basic clinical features of fractures (accidental and non-accidental) in neonates, infants, children and adolescents
- To understand the medico-legal aspects of non-accidental injury
- To describe the imaging features and basic clinical features of complex trauma in infants, children and adolescents
- To describe the imaging features and basic clinical features of common bone dysplasia (achondroplasia, osteogenesis imperfecta, congenital metabolic disorders) in children and adolescents
- To describe the imaging features and basic clinical features of rickets
- To describe the imaging features and basic clinical features of infiltrative bone marrow diseases in infants, children and adolescents
- To describe the imaging features and basic clinical features of haemoglobinopathies including sickle cell disease and thalassaemia
- To describe the imaging features and basic clinical features of bone tumours in children and adolescents
- To describe the imaging features of joint effusions in children and adolescents
- To describe the imaging features and basic clinical features of osteomyelitis and septic arthritis in children and adolescents
- To describe the imaging features and basic clinical features of juvenile rheumatoid arthritis in children and adolescents
- To describe the imaging features and basic clinical features of congenital disorders of the spine, including scoliosis (congenital and idiopathic), and dysraphism in infants, children and adolescents
- To describe the imaging features and basic clinical features of developmental dysplasia of the hip in neonates, infants, children and adolescents
- To describe the imaging features and basic clinical features of transient synovitis in children and adolescents
- To describe the imaging features and basic clinical features of Legg-Calvé-Perthes disease in children
- To describe the imaging features and basic clinical features of slipped capital femoral epiphysis in children
- To describe the imaging features and basic clinical features of congenital disorders of the ankle and foot, including congenital tarsal coalition
- To describe the imaging features and basic clinical features of osteochondrosis, including Scheuermann's disease, in children and adolescents
- To describe the imaging features and basic clinical features of soft-tissue tumours in children and adolescents

## MISCELLANEOUS

- To describe the neuro-imaging features, extracranial manifestations, diagnostic criteria and clinical features of neurofibromatosis type I
- To describe the neuro-imaging features, extracranial manifestations, diagnostic criteria and clinical features of neurofibromatosis type II
- To describe the neuro-imaging features, extracranial manifestations, diagnostic criteria and clinical features of tuberous sclerosis
- To describe the neuro-imaging features, extracranial manifestations, diagnostic criteria and clinical features of Sturge-Weber disease
- To describe the neuro-imaging features, extracranial manifestations, diagnostic criteria and clinical features of von Hippel Lindau disease
- To describe the basic imaging features of less common neurocutaneous syndromes
- To describe the imaging features and clinical features of haematological disorders in children and adolescents
- To describe the imaging features and basic clinical features of Langerhans cell histiocytosis

## SKILLS

- To perform ultrasound examinations in infants, children and adolescents and to appreciate the difference between portable and departmental ultrasound machines
- To choose the most suitable contrast material and its optimal use according to the imaging technique, the clinical problem and the age in paediatric radiology
- To observe and/or perform under supervision ultrasound of brain in the infant
- To observe and/or perform under supervision Doppler sonography of the intracranial vessels in infants, children and adolescents
- To observe and/or perform under supervision ultrasound of the hip in neonates and infants
- To observe and/or perform under supervision ultrasound of the abdomen in neonates, infants, children and adolescents
- To observe and/or perform under supervision voiding cystourethrography in infants, children and adolescents
- To observe and/or perform under supervision contrast-media studies of the gastrointestinal tract in infants, children and adolescents
- To confidently perform a treatment for intussusception
- To confidently plan a CT examination in infants, children and adolescents and to tailor it to the individual situation and age, with a dose as low as reasonably achievable
- To confidently plan an MRI examination in infants, children and adolescents and to tailor it to the individual situation and age of the patient in regard to the potential use of intravenous contrast medium and spatial resolution
- To confidently perform proper post-processing tasks of examinations in paediatric radiology, including multi-planar reformations (MPR), maximum intensity projections (MIP), minimum intensity projections (MinIP), and fusion images

## COMPETENCES AND ATTITUDES

- To confidently justify diagnostic imaging examinations in infants, children and adolescents
- To confidently choose the best-suited method for evaluating disorders in infants, children and adolescents
- To communicate with the patient and patients/care-takers in order to obtain informed consent prior to diagnostic imaging and interventional procedures in infants, children and adolescents
- To confidently choose optimal imaging parameters for radiographic, ultrasonographic, CT and MRI examinations in infants, children and adolescents
- To confidently apply techniques to reduce exposure doses for radiographic and CT examinations in infants, children and adolescents
- To confidently design imaging protocols and standard operating procedures for CT examinations infants, children and adolescents, including the appropriate application of intravenous contrast, positioning, spatial and temporal resolution, with a special focus on dose reduction
- To confidently design imaging protocols and standard operating procedures for MRI examinations of the brain and spine, including the appropriate application of intravenous contrast, spatial and temporal resolution, and the potential use of sedation
- To supervise and teach technical staff to ensure that appropriate images of infants, children and adolescents are obtained
- To confidently judge the quality of imaging examinations in infants, children and adolescents and to devise strategies to improve image quality
- To confidently interpret and report radiographs, ultrasonographic examinations, CT studies and MRI examinations of infants, children and adolescents
- To report oncological studies in infants, children and adolescents according to international standards (RECIST, SIOPEN, WHO) applicable to the specific situation
- To appreciate own limitations and to identify when it is appropriate to obtain assistance in interpreting and reporting images of infants, children and adolescents
- To confidently identify urgent and/or unexpected findings in imaging examinations of infants, children and adolescents and to communicate these timely and properly
- To empathically communicate with patients and their parents/care-takers in order to explain their imaging findings
- To perform at multi-disciplinary conferences and tumour boards for diseases of infants, children and adolescents

## B-II-13

# UROGENITAL RADIOLOGY

The field of urogenital radiology includes all aspects of medical imaging (diagnostic and interventional) of the kidneys, retroperitoneum, bladder, as well as male and female reproductive systems including aspects of the anatomy and pathophysiology of the respective diseases. This field of imaging includes various techniques (ultrasound, Doppler, conventional X-ray imaging, computed tomography, magnetic resonance imaging, angiography and interventional procedures).

Trainees should familiarise themselves with the field of urogenital radiology and gain knowledge, skills and competences in this field. Preferably, arrangements should be made within the training scheme for secondment to urology and/or gynaecology. Exposure to all imaging and interventional techniques used in urogenital radiology should be achieved.

## KNOWLEDGE

### NORMAL ANATOMY AND VARIANTS

- To describe the normal anatomy of the retroperitoneal spaces and pathways
- To describe the triple obliquity of the kidney
- To list the criteria of normality of the pyelocaliceal system on CT urography
- To describe normal variants, including junctional parenchymal defect, column of Bertin's hypertrophy, fetal lobulation, or lipomatosis of the sinus, and to accurately differentiate these variants from disease
- To describe the anatomy of the bladder wall
- To describe the segments of the male urethra and the location of the urethral glands
- To understand the physiology of micturition
- To describe the zonal anatomy of the prostate
- To describe the imaging features of prostatic zonal anatomy with ultrasound and MRI
- To describe the ultrasound anatomy of scrotal structures (testicular and extratesticular)
- To describe the Doppler anatomy of the testicular and extratesticular vessels

## RENAL PHYSIOLOGY AND KINETICS OF CONTRAST AGENTS

- To describe the physiology of renal excretion of contrast agents
- To describe enhancement curves within renal compartments after intravascular injection of contrast agents
- To define the potential nephrotoxicity of contrast media and to list risk factors of contrast induced nephrotoxicity
- To list methods to reduce the risk of contrast nephrotoxicity
- To list measures to reduce the risk of contrast media nephrotoxicity
- To have an understanding of nephrogenic systemic fibrosis (NSF) including the definition of NSF, the clinical features and the risk factors
- To describe the appropriate use of Gadolinium-based contrast media in patients at risk

## CONGENITAL

- To list main renal malformations, such as ectopia, duplications or fusions
- To describe congenital malformations of the bladder and urethra
- To describe congenital malformations of the prostate, seminal vesicles, vas, and the testes

## ADRENAL GLANDS

- To describe the imaging and clinical features of adrenal insufficiency
- To describe the imaging features and basic clinical features of benign solid tumours of the adrenal glands
- To describe the imaging features and basic clinical features of adrenal cysts
- To describe the imaging features and basic clinical features of malignant tumours of the adrenal gland in the adult and in the paediatric population
- To describe the management and principles of differential diagnosis of incidentally discovered lesions of the adrenal glands
- To describe the imaging features and basic clinical features of adrenal trauma



## KIDNEY AND URETER

- To describe the imaging features of vascular disorders of the kidney
- To describe the imaging features and basic clinical features of medical nephropathies
- To describe the imaging features and basic clinical features of infections of the kidney and/or urinary tract
- To describe the imaging features of cystic diseases of the kidney
- To describe the imaging features and basic clinical features of tumours of the kidney
- To describe the imaging features of calculi of the urinary tract
- To describe the imaging features and basic clinical features of urinary obstruction
- To describe the imaging features and basic clinical features of tumours of the ureter
- To describe the imaging features after renal transplantation
- To describe the imaging features and basic clinical features of trauma to the kidneys and/or ureters
- To describe the principles of CT urography including the main indications, choice of technique, choice of contrast agent and dose

## BLADDER AND URETHRA

- To describe the imaging features and basic clinical features of inflammatory disorders of the bladder
- To describe the imaging features and basic clinical features of tumours of the bladder
- To describe the imaging features of urinary diversion
- To describe the imaging features and basic clinical features of urinary outflow obstructions
- To describe the imaging features and basic clinical features of incontinence and functional disorders of the bladder
- To describe the imaging features and basic clinical features of strictures of the urethra
- To describe the imaging features and basic clinical features of urethral diverticula
- To describe the imaging features and basic clinical features of trauma to the bladder and urethra
- To describe the principles of cystourethrography including the main indications, choice of technique, choice of contrast agent, dose, film timing and indications

## MALE REPRODUCTIVE SYSTEM

- To describe the imaging features and basic clinical features of inflammatory disorders of the prostate
- To describe the imaging features and basic clinical features of benign prostatic hyperplasia
- To describe the imaging features and basic clinical features of tumoral pathology of the prostate
- To describe the imaging features and basic clinical features of inflammatory disorders of the testes
- To describe the imaging features and basic clinical features of tumoral pathology of the testes
- To describe the imaging features and basic clinical features of testicular torsion
- To describe the imaging features and basic clinical features of Peyronie's disease
- To describe the various imaging manifestations of impotence
- To describe the imaging features and basic clinical features of priapism
- To describe the imaging features and basic clinical features of tumal pathology of the penis
- To describe the imaging features and basic clinical features of traumatic lesions of the penis

## SKILLS

- To choose and/or guide the choice of the most appropriate imaging examination according in urogenital radiology related to the clinical problem and the patients history, including any previous radiological examinations
- To choose the most suitable contrast material and its optimal dose and use according to the imaging technique, the clinical problem, and relevant patient related criteria in urogenital radiology
- To identify patients at risk of contrast nephrotoxicity
- To take measures to reduce the risk of contrast nephrotoxicity
- To take measures to reduce the risk of contrast media nephrotoxicity
- To identify patients at risk to develop NSF
- To confidently perform ultrasound examinations of the kidneys, urinary tract, and of the male reproductive system
- To perform Doppler spectrum analysis on intrarenal vessels (for resistive/pulsatility index measurement) and on the entire course of the proximal renal arteries for velocity calculation
- To confidently perform cystourethrography
- To confidently plan a CT examination in urogenital radiology and to tailor it to the individual situation with a dose as low as reasonably achievable
- To confidently perform state-of-the-art CT urography
- To confidently plan an MRI examination in urogenital radiology and to tailor it to the individual patient in regard to spatial resolution and the potential use of intravenous contrast medium
- To observe and/or perform under supervision image-guided biopsies, e.g. renal parenchymal biopsies, biopsies of kidney masses, and biopsies of retroperitoneal masses
- To observe and/or perform under supervision image-guided drainage procedures related to the urogenital tract
- To observe and/or perform under supervision percutaneous nephrostomy
- To confidently perform proper post-processing tasks of examinations in urogenital radiology, including multi-planar reformations (MPR), maximum intensity projections (MIP), minimum intensity projections (MinIP), and fusion images for diagnostic purposes and for imaging-guided interventional procedures and therapies

## COMPETENCES AND ATTITUDES

- To confidently justify diagnostic imaging examinations in urogenital radiology
- To confidently choose or guide the best-suited method for evaluating disorders in urogenital radiology
- To communicate with the patient in order to obtain informed consent prior to diagnostic imaging studies and interventional procedures in urogenital radiology
- To confidently choose optimal imaging parameters for radiographic, ultrasonographic, CT and MR examinations in urogenital radiology
- To confidently apply techniques to reduce radiation exposure doses for radiographic and CT examinations in urogenital radiology
- To confidently design imaging protocols and standard operating procedures for CT examinations in urogenital radiology, including the appropriate application of intravenous contrast, positioning, spatial and temporal resolution, with a special focus on dose reduction
- To confidently design imaging protocols and standard operating procedures for MR examinations in urogenital radiology, including the appropriate application of intravenous contrast, and of spatial and temporal resolution
- To supervise and teach technical staff to ensure that appropriate images of the urogenital system are obtained, adjusted to the clinical problem
- To confidently judge the quality of imaging examinations in urogenital radiology and to provide strategies to improve image quality
- To confidently interpret and report radiographs, ultrasonographic examinations, CT studies and MRI examinations in urogenital radiology
- To report oncological studies in urogenital radiology according to international standards (RECIST, WHO) applicable to the specific situation
- To appreciate one's own limitations and to identify when it is appropriate to obtain an additional opinion (-s) in performing, interpreting and reporting images of the urogenital system
- To confidently identify urgent and/or unexpected findings in imaging examinations of the urogenital system and to communicate these findings timely and properly with the referring physician or his replacer responsible for patient care
- To empathically communicate with patients and their families in order to explain their imaging findings of the urogenital system, whenever appropriate
- To actively contribute at multi-disciplinary meetings and tumour boards for diseases of the urogenital system

## 2. ORGANISATION OF TRAINING

### A. SCHEDULE AND LENGTH OF TRAINING

The revised European Training Curriculum for Radiology continues to outline a five-year (three + two) training period, consisting of Level I Training over the first three years followed by a more flexible Level II Training with potential special interest (elective) rotations during the last two years.

#### LEVEL I TRAINING: YEARS 1-3

During the first three years of training, the fundamentals of undertaking and interpreting a wide range of imaging techniques and disease manifestations remain the essential curriculum component.

A detailed knowledge of normal imaging anatomy and physiology should be gained in the early stages of training. Early in this three-year period, trainees should acquire the necessary knowledge of basic sciences, the physical basis of image formation in all imaging techniques, picture archiving and communication systems (PACS), radiology and hospital information systems, quality control and quality management, radiation physics, radiation biology, radiation protection, anatomy, physiology, cell biology and molecular structure, biochemistry and techniques related to radiological procedures. Knowledge must also be gained of the pharmacology and application of contrast media and the treatment of adverse reactions to them. A basic understanding of computer science needs also to be acquired. The fundamentals of clinical research, statistics and evidence-based medicine as applied to radiology should be taught as well; ideally, there should be exposure to active radiological research with the option to perform own scientific projects. The trainee should moreover become familiar with a wide range of radiological skills including the performance of a variety of procedures.

Radiology is a clinical specialty, and while the extent of direct clinical exposure will vary from country to country, the European Training Curriculum for Radiology promotes the concept that good extra-radiological clinical competence is an essential component of radiology training. This experience is required to allow the radiologist to provide a safe medical environment for patients within the Radiology Department and during image-guided interventions. Moreover, training should ascertain that the reporting of diagnostic imaging will have a clinically relevant and patient-focused emphasis.

Experience in emergency radiology is an integral component of radiology training, and must be accommodated during Level I Training as to provide the necessary knowledge, skills, competences and attitudes within the training programme. Ideally, emergency radiology should be taught at the very beginning of radiological training. The identification and communication of urgent and unexpected findings should already be trained at this point in time. The role of the radiologist as a communicator with patients and families and as a collaborator with other clinical specialists should moreover be emphasized.

Multidisciplinary and clinico-radiology conferencing, including the conduction of tumour boards for various organ systems, has become an integral component of medical care and decision-making.

Frequently, such conferencing is conducted under the chairmanship of a radiologist and within a radiology department, emphasising the importance of training and direct experience of such meetings within the modern radiology curriculum. During Level I Training, participation in multi-disciplinary conferences and tumour boards should be encouraged and such conferences may be conducted by the trainee under supervision.

A written or electronic logbook of activity during Level I Training should be maintained. This should provide a formal validated record of competencies achieved and examinations performed and should form an integral part of regular assessments of satisfactory training.

The following fields of radiology should be taught during Level I Training and are outlined in the European Training Curriculum for Radiology:

B-I-1 Breast Radiology

B-I-2 Cardiac and Vascular Radiology

B-I-3 Chest Radiology

B-I-4 Emergency Radiology

B-I-5 Gastrointestinal and Abdominal Radiology

B-I-6 Gynaecological and Obstetric Radiology

B-I-7 Head and Neck Radiology

B-I-8 Interventional Radiology

B-I-9 Musculoskeletal Radiology

B-I-10 Neuroradiology

B-I-11 Paediatric Radiology

B-I-12 Urogenital Radiology

B-I-13 Nuclear medicine as basic training

B-I-14 Radiation Protection Education and Training

B-I-15 Principles of Imaging Technology & Molecular Imaging

B-I-16 Communication and Management

B-I-17 Research and Evidence-Based Medicine

A three-month rotation in nuclear medicine facilities equipped with conventional and hybrid imaging equipment, PET-CT and SPECT/CT scanner should be available during basic training, either in the home department or in an adjacent or offsite nuclear medicine teaching department in order to become familiar with basic methods in this specialty.

## LEVEL II TRAINING: YEARS 4-5

The European Training Curriculum for Radiology recognises that most European radiologists now work in teams, where individual members will have specific skills and competences. This increasing training in specific areas of interest is encouraged, while it is recognized that general competences should be maintained also by subspecialised radiologists and that general radiologists are needed as well. The European Society of Radiology emphasises that during the fourth and fifth years a developing knowledge in general radiology should continue to be nourished. Elective interest training during this period may apply to two areas of interest, while training in the other areas of radiology should continue as well. For interested trainees, options to actively perform radiological research projects should ideally be offered.

A written or electronic logbook of activity during Level II Training should be maintained. This should provide a formal validated record of competencies achieved and examinations performed and should form an integral part of regular assessments of satisfactory training. Level II Training by no means substitutes Level III Training.

The following fields of radiology are outlined in the Level 2 section of the European Training Curriculum for Radiology:

---

B-II-1 Breast Radiology

---

B-II-2 Cardiac and Vascular Radiology

---

B-II-3 Chest Radiology

---

B-II-4 Emergency Radiology

---

B-II-5 Gastrointestinal and Abdominal Radiology

---

B-II-6 Gynaecological and Obstetric Radiology

---

B-II-7 Head and Neck Radiology

---

B-II-8 Interventional Radiology

---

B-II-9 Musculoskeletal Radiology

---

B-II-10 Neuroradiology

---

B-II-11 Oncologic Imaging

---

B-II-12 Paediatric Radiology

---

B-II-13 Urogenital Radiology

---

The recommendations of the European Training Curriculum are not an end in themselves, but should be interpreted in the context of understanding the seamless transition from training to lifelong continuous medical education (CME) and continuous professional development (CPD). An appreciation of this continuum should be instilled at an early stage of training already.

## LEVEL III TRAINING: BEYOND YEAR 5

Level III Training is a formal, full-immersion training in a radiological subspecialty after the completion of radiology (Level I and Level II) training. Parts of Level II Training in a subspecialty may be counted for subspecialisation. However, full subspecialisation always requires further Level III (subspecialty) Training beyond Level I and Level II Trainings. Level III Training curricula are beyond the scope of the present document.

## B. CURRICULUM OF TRAINING / INFRASTRUCTURAL ASPECTS

The specialty of radiology involves all aspects of medical imaging that provide information about morphology, function, cell activity and those aspects of interventional radiology or minimally invasive therapy (MIT) that fall under the remit of the radiology department.

### TRAINING MODULES

Trainees should participate in clinical radiology examinations and activities whose extent and complexity should gradually increase in line with experience. It is important that trainees systematically rotate through all sections of the radiology department at an early stage to become conversant with the principles of the main techniques and to gain a working knowledge of all relevant imaging methods.

The precise structure of the system-based modules will vary from country to country and from department to department, but the time balance should reflect the importance of the system to the core of radiological practice.

Training should be under the direction and supervision of the radiology department of a large teaching hospital, although models for clinic- and academy-based training also exist. Each training programme should outline the educational goals and objectives of the programme with respect to knowledge, skills, competences and other attributes of trainees at each level of training and for each major training task.

Most radiology training should be acquired at a single teaching institution where all or most subspecialty disciplines are available. However, several institutions can pool their resources in order to provide complete access to all techniques and specialties. Ideally, this department should be affiliated to a university, and should have full and close collaboration with a medical physics department. The availability of a 24 hour Emergency Department is recommended. Ready access to university anatomy, biochemistry, statistics, physics and pathology departments should be available to all training centres. If at all possible, in-house physics training should be available. Teaching principles should include didactic lectures, tutorials etc., but there should also be a large component of one-to-one apprenticeship relations with the staff faculty.

The spectrum of patient and investigative material available during training should be sufficient to enable the trainee to gain experience in all fields of radiology. When possible, training should ideally be integrated into a single department; however, attendees of an institution with limited specialties may be required to ensure comprehensive training elsewhere.

Within each teaching department, a local tutor or mentor with direct responsibility for in-house training should be appointed to ensure that an appropriate proportion of service versus training time be maintained.

Regular assessments should be carried out on a yearly basis and easy access for trainees to local coordinators should be encouraged.

The trainee should be involved in the radiological examination and diagnosis of patients presenting in the emergency department and should be able to appropriately evaluate patients who are severely or critically ill. It is not anticipated that a trainee would enter into an emergency on-call rotation entailing clinical responsibility until the end of the first year of training. An objective evaluation (examination) should take place at the end of the first year and satisfactory performance should be a prerequisite for unsupervised emergency room and/or supervised on-call duties. Competence in dealing with acute medical emergencies arising within the radiology department should be ensured.

All reporting should be supervised and all radiology reports should be discussed and validated with the trainee by an experienced staff radiologist.

Patient safety specifically with reference to radiological practice should be thoroughly emphasised. Such safe radiology practice should include validation of any request for radiological examination with respect to risk factors, exposure to ionizing radiation and possible alternatives employing non-ionising radiation.

The fully trained radiologist should be capable of working independently when solving most common clinical problems and those undertaking interventional procedures should also have sufficient clinical background knowledge to accept direct referrals and to clinically manage patients in the immediate time frame surrounding such interventions.



## EQUIPMENT

Only departments with adequate imaging equipment and services should be approved for training. The equipment should comply with radiological safety standards and should be in good technical condition. Technical efficiency, security, radiation safety and controls should be of an adequate standard and conform to agreed national quality control criteria. Radiation protection should be organised and radiation should be monitored according to European standards. The down-time of the equipment for maintenance and repair should be minimal and should not interfere with training.

The techniques for adequate radiological training will depend on local availability, but should include the following:

---

Conventional radiography (including fluoroscopy)

---

Mammography

---

Ultrasound

---

Computed tomography

---

Digital subtraction angiography

---

Interventional radiology

---

Magnetic resonance imaging

---

Access to nuclear medicine with hybrid imaging equipment

---

## READING FACILITIES AND TEACHING MATERIALS

Access to quiet reading areas with internet portals should be available to trainees within the department. Audio-visual equipment and rooms should be available in the radiology department, sufficient to enable the implementation of the teaching programme. An adequate supply of teaching materials should include text books and journals (either in print edition or in an online version). Teaching facilities should include access to online medical publications, teaching aids (including EURORAD etc.) and a full radiology library. A wide range of e-learning facilities have now been developed within ESR, and are available on the website. Active in-house development of a teaching file represents a very valuable stimulus for trainees and is encouraged.

## COURSE PARTICIPATION

Attendance at outside courses and scientific congresses / meetings will depend on the stage of training and the relevance of the courses to the trainee's stage of training. Throughout the five years, attendance at a minimum of two relevant international and five national congresses or courses is encouraged. Presentation of original research by the trainees at these scientific meetings should be encouraged. Such participation should be logged and recorded on an annual basis. A spirit of academic excellence should be fostered within the department, including a pride in profiling the department's achievement at local, national and international scientific gatherings, and in presenting scientific results in renowned, peer-reviewed national and international journals. Authorship of research publications and peer-reviewed journals should be encouraged and ongoing mentoring in this area should be made available by more senior academic staff. PhD programmes offer an excellent tool to train residents in radiology in scientific work and are expected to play a greater role in research training in radiology in the future throughout Europe.

Advice on research principles and protocols is freely available to ESOR members through the Research Committee of the ESR.

## PROPORTION OF RADIOLOGICAL TRAINING IN UNIVERSITY, TEACHING, NON-UNIVERSITY AND/OR PRIVATE INSTITUTIONS

Rotations through small and subspecialized hospitals may frequently supplement basic radiological training and are to be recommended for limited periods. Ready access to university level physics and pathology departments should exist for all training centres. Ideally, in-house physics training should be available.

All the university departments and training hospitals should be part of a coordinated national or federal training scheme. Training schemes should ideally be subject to single national organisations to standardise the educational experience and maximise efficiencies.

## EUROPEAN SCHOOL OF RADIOLOGY

The European School of Radiology (ESOR) offers complementary and continuing education to residents and young radiologists through visiting schools, visiting seminars, scholarships, exchange programmes for fellowships, and tutorials, thus enhancing and ensuring the further development of young radiologists during their training.

The ESR Education Committee encourages young radiologists to participate in the programmes and to benefit from internationally renowned faculties and/or training in pre-selected, highly esteemed reference training centres in Europe and beyond (see <http://www.myesr.org>).

## C. ASSESSMENT AND EVALUATION

Assessment is defined as the process, by which information is obtained in relation to known objectives or goals with a further subdivision into formative and summative assessments. Evaluation is defined as the process designed to provide information that aids in judging a given situation.

Formal trainee appraisal and assessment should take place at regular intervals (at least once a year). In order to verify that appropriate modular training has been obtained, this assessment should include appraisal of the log book referred to above. Assessments should also cover clinical and technical competencies, including interpersonal skills and suitability as a clinically active doctor. As part of the assessment process, trainees should be given an opportunity to provide their own observations on training facilities and teaching personnel on a confidential basis.

On completion of the training period the radiologist is expected to be capable of working independently and unsupervised in a hospital or outpatient facility.

At the end of training, objective measurement of an achieved standard should be made depending on national custom and practice.

A European Board of Radiology (EBR)-coordinated European Diploma in Radiology (EDiR) is available to supplement these national evaluations (see [http://www.myesr.org/cms/website.php?id=/29634/en/education\\_training/elearning/european\\_diploma\\_in\\_radiology\\_edir\\_h.htm](http://www.myesr.org/cms/website.php?id=/29634/en/education_training/elearning/european_diploma_in_radiology_edir_h.htm)).

## D. GOVERNANCE

### ACCREDITATION OF TRAINING DEPARTMENTS

Accreditation of training departments by a competent and independent authority coordinated through either the national society or a national authority with responsibility for training should be performed.

It is recommended that accreditation should be carried out every five years and should include the following:

Number and type of radiological examinations (the spectrum of patient and investigative material available should be sufficient to enable the trainee to gain adequate experience for full radiological training)

---

Number, type and standard of imaging equipment

---

Trainee access to the full range of imaging techniques

---

Adequacy of trainer–trainee ratios

---

Teaching programmes available

---

Teaching materials

---

Research activity of trainees and of the department in general

---

The European Training and Assessment Programme (ETAP), which provides a formal evaluation of training programmes, is a programme within ESR and is available to all member national societies. For this purpose the programme provides on-the-ground assessment and also gives advice on accreditation programmes to be run nationally.

### RELATIONSHIP OF TRAINING PROGRAMME WITH REGULATORY AUTHORITIES

This will vary greatly throughout Europe, but it is of importance that the central regulatory authorities cooperate and that easy cross-referencing takes place among the bodies responsible for radiological education and licensing regulatory authorities, teaching centres, local hospital administrations etc. Adequate educational funding budgets should be ring-fenced within health care structures.

## II. TRAINING REQUIREMENTS FOR TRAINERS

### 1. PROCESS FOR RECOGNITION AS TRAINER

All trainers shall be board-certified radiologists holding a nationally recognized qualification as a radiologist. Moreover, they should have teaching experience both in regard to undergraduate and post-graduate teaching.

Within each teaching department, a local tutor or mentor with direct responsibility for in-house training should be appointed to ensure that an appropriate proportion of service versus training time be maintained.

The number of qualified radiologists with teaching functions in the department should be sufficient to fulfil all the needs of teaching in each major subspecialty area and in general radiology. The expertise of the teaching staff should cover a broad spectrum and include the subspecialties as outlined in the detailed curriculum for the initial structured common programme. If necessary, departmental support should be given for modular training outside the base hospital.

Teaching staff should be motivated and ideally several should be pursuing a university-based academic career pathway. In-house teaching should include didactic lectures, small tutorial groups and one-to-one apprenticeship experience. The teachers should ideally attend teacher-targeted training courses and should be fully integrated into the overall university educational process. Where examinations are a feature of training all teachers should experience the appropriate practical examinations and participate as examiners.

### 2. QUALITY MANAGEMENT FOR TRAINERS

An active quality management program training for the trainer and training program should be instituted at all teaching centres.

This should include regular audits as well as feed-back systems between the trainers and the trainees.

It needs to be ascertained at regular intervals that the standards for education in radiology are met by the trainers.

Educational courses on pedagogical concepts, teaching methods and quality management should be attended at regular intervals.

### III. TRAINING REQUIREMENTS FOR TRAINING INSTITUTIONS

## 1. PROCESS FOR RECOGNITION AS TRAINING CENTER

### A. REQUIREMENTS ON STAFF AND CLINICAL ACTIVITIES

Training should be under the direction and supervision of the radiology department of a large teaching hospital, although models for clinic- and academy-based training also exist. Each training programme should outline the educational goals and objectives of the programme with respect to knowledge, skills, competences and other attributes of trainees at each level of training and for each major training task.

Most radiology training should be acquired at a single teaching institution where all or most subspecialty disciplines are available. However, several institutions can pool their resources in order to provide complete access to all techniques and specialties. Ideally, this department should be affiliated to a university, and should have full and close collaboration with a medical physics department. The availability of a 24 hour Emergency Department is recommended. Ready access to university anatomy, biochemistry, statistics, physics and pathology departments should be available to all training centres. If at all possible, in-house physics training should be available. Teaching principles should include didactic lectures, tutorials etc., but there should also be a large component of one-to-one apprenticeship relations with the staff faculty.

The spectrum of patient and investigative material available during training should be sufficient to enable the trainee to gain experience in all fields of radiology. When possible, training should ideally be integrated into a single department; however, attendees of an institution with limited specialties may be required to ensure comprehensive training elsewhere.

The number of qualified radiologists with teaching functions in the department should be sufficient to fulfil all the needs of teaching in each major subspecialty area and in general radiology. The expertise of the teaching staff should cover a broad spectrum and include the subspecialties as outlined in the detailed curriculum for the initial structured common programme. If necessary, departmental support should be given for modular training outside the base hospital.

Teaching staff should be motivated and ideally several should be pursuing a university-based academic career pathway. In-house teaching should include didactic lectures, small tutorial groups and one-to-one apprenticeship experience. The teachers should ideally attend teacher-targeted training courses and should be fully integrated into the overall university educational process. Where examinations are a feature of training all teachers should experience the appropriate practical examinations and participate as examiners.

A spirit of academic excellence should be fostered within the department, including a pride in profiling the department's achievement at local, national and international scientific gatherings, and in presenting scientific results in renowned, peer-reviewed national and international journals. Authorship of research publications and peer-reviewed journals should be encouraged and ongoing mentoring in this area should be made available by more senior academic staff. PhD programmes offer an excellent tool to train residents in radiology in scientific work and are expected to play a greater role in research training in radiology in the future throughout Europe.

## B. REQUIREMENTS ON EQUIPMENT AND ACCOMMODATION

Only departments with adequate imaging equipment and services should be approved for training. The equipment should comply with radiological safety standards and should be in good technical condition. Technical efficiency, security, radiation safety and controls should be of an adequate standard and conform to agreed national quality control criteria. Radiation protection should be organised and radiation should be monitored according to European standards. The down-time of the equipment for maintenance and repair should be minimal and should not interfere with training.

The techniques for adequate radiological training will depend on local availability, but should include the following:

---

Conventional radiography (including fluoroscopy)

---

Mammography

---

Ultrasound

---

Computed tomography

---

Digital subtraction angiography

---

Interventional radiology

---

Magnetic resonance imaging

---

Access to nuclear medicine

---

Access to quiet reading areas with internet portals should be available to trainees within the department. Audio-visual equipment and rooms should be available in the radiology department, sufficient to enable the implementation of the teaching programme. An adequate supply of teaching materials should include text books and journals (either in print edition or in an online version). Teaching facilities should include access to online medical publications, teaching aids (including EURORAD etc.) and a full radiology library. A wide range of e-learning facilities have now been developed within ESR, and are available on the website. Active in-house development of a teaching file represents a very valuable stimulus for trainees and is encouraged.

## 2. QUALITY MANAGEMENT WITHIN TRAINING INSTITUTIONS

An active quality management program should be instituted in all training institutions. This should include continuous improvement processes via a plan-do-check-act cycle, regular internal and external audits and continuous educational endeavours.

Accreditation of training departments by a competent and independent authority coordinated through either the national society or a national authority with responsibility for training should be performed.

It is recommended that accreditation should be carried out every five years and should include the following:

---

Number and type of radiological examinations (the spectrum of patient and investigative material available should be sufficient to enable the trainee to gain adequate experience for full radiological training)

---

Number, type and standard of imaging equipment

---

Trainee access to the full range of imaging techniques

---

Adequacy of trainer-trainee ratios

---

Teaching programmes available

---

Teaching materials

---

Research activity of trainees and of the department in general

---

Manpower planning

---

Clinical governance

---

The European Training and Assessment Programme ([www.myESR.org/ETAP](http://www.myESR.org/ETAP)), which provides a formal evaluation of training programmes, is a programme within ESR and is available to all member national societies. For this purpose the programme provides on-the-ground assessment and also gives advice on accreditation programmes to be run nationally.



Coordination: ESR Office, Neutorgasse 9, 1010 Vienna, Austria  
Phone: +43 1 533 40 64-28 | Fax: +43 1 533 40 64-448  
E-mail: [boardaffairs@myesr.org](mailto:boardaffairs@myesr.org) | [www.myESR.org](http://www.myESR.org)  
All data as per date: March 2016  
ESR accepts no responsibility for errors or misprints

[WWW.MYESR.ORG/TRAININGCURRICULUM](http://WWW.MYESR.ORG/TRAININGCURRICULUM)

**REVISED EUROPEAN TRAINING CURRICULUM FOR RADIOLOGY**